

CLINICAL PRACTICE GUIDELINES

Management of toxicities from immunotherapy: ESMO Clinical Practice Guidelines for diagnosis, treatment and follow-up[†]

J. B. A. G. Haanen¹, F. Carbonnel², C. Robert³, K. M. Kerr⁴, S. Peters⁵, J. Larkin⁶ & K. Jordan⁷, on behalf of the ESMO Guidelines Committee*

¹Netherlands Cancer Institute, Division of Medical Oncology, Amsterdam, The Netherlands; ²Department of Gastroenterology, Kremlin Bicêtre Hospital, Assistance Publique-Hôpitaux de Paris (AP-HP), Paris, France; ³Department of Medicine, Dermatology Unit, Gustave Roussy Cancer Campus, Villejuif, France; ⁴Department of Pathology, Aberdeen University Medical School & Aberdeen Royal Infirmary, Aberdeen, UK; ⁵Oncology Department, Centre Hospitalier Universitaire Vaudois (CHUV), Lausanne, Switzerland; ⁶Royal Marsden Hospital NHS Foundation Trust, London, UK; ⁷Department of Medicine V, Hematology, Oncology and Rheumatology, University Hospital of Heidelberg, Heidelberg, Germany

*Correspondence to: ESMO Guidelines Committee, ESMO Head Office, Via L. Taddei 4, CH-6962 Viganello-Lugano, Switzerland. E-mail: clinicalguidelines@esmo.org

[†]Approved by the ESMO Guidelines Committee: May 2017.

General aspects of immune checkpoints blockade

Incidence and epidemiology

Immunotherapy with monoclonal antibodies (MoAbs) targeting cytotoxic T lymphocyte-associated antigen 4 (CTLA4) and the programmed death-1 receptor (PD-1) and its ligand PD-L1 has become standard of care for an increasing number of indications (Table 1). Therefore, an increasing number of patients will be exposed to these drugs with a chance of developing toxicities from these treatments. Depending on the immune checkpoint that is targeted, the incidence of toxicity varies. Toxicities from immune checkpoint inhibitors (ICPIs) can be divided into infusion reactions and immune-related adverse events (irAEs) or adverse events of special interest (AEoSI). The latter will be the subject of these Clinical Practice Guidelines. Any organ or tissue can be involved, although some irAEs occur much more commonly than others. The most frequently occurring irAEs affect skin, colon, endocrine organs, liver and lungs. Others are very infrequent, but may be very serious, even lethal, such as neurological disorders and myocarditis.

Ipilimumab-associated immune-related toxicities

irAEs from ipilimumab, anti-CTLA4, at a dose of 3 mg/kg, have been documented to occur in 60%–85% of patients [1, 2], mostly grades 1 and 2, but between 10% and 27% of patients develop

grade 3 to 4 toxicities, and 2.1% ipilimumab-related deaths have been reported in the first phase III trial [1]. The onset of these toxicities varies but usually starts within the first 8 to 12 weeks of initiation of treatment [an example of onset of adverse events (AEs) upon ipilimumab treatment is depicted in Figure 1], with skin toxicities often being the first to develop. These toxicities are dose-dependent as no grade 3 to 4 AEs were observed at a dose of 0.3 mg/kg ipilimumab, whereas these toxicities increased to 30% with a dose of 10 mg/kg [3]. In the adjuvant setting with ipilimumab 10 mg/kg followed by a maintenance dose, the recorded grade 3 to 4 irAE rate was 41.6%, and the grade 5 irAE rate 1.1% [4].

PD-1/PD-L1 blockade immune-related toxicities

The most frequently reported AE with anti-PD-1/PD-L1 is fatigue. Incidence of fatigue, of which the pathogenesis is poorly understood, across single drug studies, is 16%–37% for anti-PD-1 and 12%–24% for anti-PD-L1 [5]. Only in a minority of patients fatigue can be attributed to hypothyroidism. High-grade toxicities from anti-PD-1 (either nivolumab or pembrolizumab) are less common than for the CTLA4 blocking agent ipilimumab. For nivolumab, any treatment-related AE was documented in 74%–85% of patients, with 12%–20% being grade 3 and 4 [2, 6, 7] for metastatic melanoma patients, 58% and 7%, respectively, for advanced cisplatin refractory squamous non-small-cell lung cancer (NSCLC) [8], 69% and 10%, respectively, for metastatic cisplatin refractory non-squamous NSCLC [9] and 79% and

Table 1. Approved indications for ICPIs

Drug	Indications	EMA/FDA approval
Ipilimumab	Metastatic melanoma Adjuvant therapy stage III melanoma	EMA + FDA FDA
Nivolumab	Metastatic melanoma 2 nd line metastatic NSCLC 2 nd line metastatic RCC Classical Hodgkin's disease ^a Recurrent or metastatic SCCHN ^b Locally advanced or metastatic UCC ^c	EMA + FDA EMA + FDA EMA + FDA EMA + FDA EMA + FDA EMA + FDA
Pembrolizumab	Metastatic melanoma 2 nd line metastatic NSCLC (PD-L1 ≥ 1%) 1 st line metastatic NSCLC (PD-L1 ≥ 50%) 1 st line metastatic NSCLC in combination with pemetrexed + carboplatin Classical Hodgkin's disease Locally advanced or metastatic UCC ^c MSI-H or MMR deficient metastatic malignancies ^e	EMA + FDA EMA + FDA EMA + FDA FDA EMA ^a + FDA ^d FDA FDA
Atezolizumab	Locally advanced or metastatic UCC ^c 2 nd line metastatic NSCLC	FDA FDA
Avelumab	Locally advanced or metastatic UCC ^c Metastatic Merkel cell carcinoma	FDA FDA
Durvalumab	Locally advanced or metastatic UCC ^c	FDA
Ipilimumab + nivolumab	Metastatic melanoma	EMA + FDA

^aFor the treatment of patients with cHL who have relapsed or progressed after auto-HSCT and post-transplantation brentuximab vedotin. ^bFor the treatment of patients with recurrent or metastatic SCCHN with disease progression on or after platinum-based therapy. ^cFor patients with locally advanced or metastatic UCC who have disease progression during or following platinum-containing chemotherapy or within 12 months of neoadjuvant or adjuvant treatment with platinum-containing chemotherapy. ^dFor the treatment of adult and pediatric patients with cHL who are refractory or have relapsed after 3 or more lines of therapy. ^eFor adult and paediatric patients with unresectable or metastatic, MSI-H or dMMR that have progressed following prior treatment and who have no satisfactory alternative treatment options or with MSI-H or dMMR CRC that has progressed following treatment with a fluoropyrimidine, oxaliplatin, and irinotecan.

Auto-HSCT, autologous hematopoietic stem cell transplantation; cHL, classic Hodgkin's lymphoma; CRC, colorectal cancer; dMMR, deficient MMR; EMA, European Medicines Agency; FDA, Food and Drug Administration; ICPI, immune checkpoint inhibitor; MMR, DNA mismatch repair; MSI-H; microsatellite instability-high; NSCLC, non-small-cell lung cancer; PD-L1, programmed death ligand 1; RCC, renal cell carcinoma; SCCHN, squamous cell carcinoma of the head and neck; UCC, urothelial carcinoma.

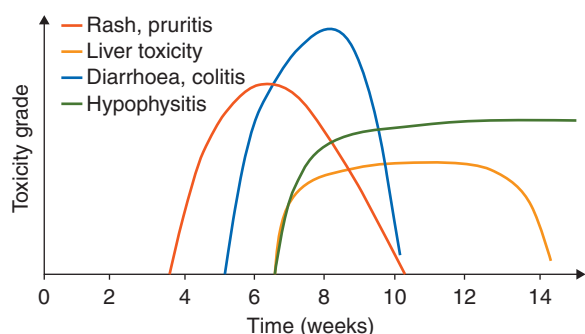


Figure 1. Timing of occurrence of immune-related adverse events following ipilimumab treatment. Reprinted from [86] with permission. © 2012 American Society of Clinical Oncology. All rights reserved.

19%, respectively, for tyrosine kinase inhibitor refractory metastatic renal cell carcinoma [10].

For pembrolizumab, the Keynote-002 study, comparing pembrolizumab at doses of 2 and 10 mg/kg to chemotherapy in ipilimumab pre-treated metastatic melanoma, showed grade 1 to 2 irAEs in 57%–60% and grade 3 to 4 toxicity in 14% of patients [11]. In the Keynote-006 study comparing pembrolizumab, given at 10 mg/kg either every 3 or 2 weeks, to ipilimumab, treatment-related toxicity was observed in 73%–80% of patients, with 10%–13.5% having grade 3 or higher AEs [12]. In a similar design to the Keynote-002, the Keynote-010 study in cisplatin refractory NSCLC patients compared pembrolizumab (2 mg/kg) and pembrolizumab (10 mg/kg) with docetaxel. The reported treatment-related AEs for the pembrolizumab-treated groups were 63% and 66% for any AE, and 13% and 16% for grade 3 to 4 toxicities, respectively [13]. In the Keynote-024 study pembrolizumab given at 200 mg flat dose every 3 weeks was compared with cisplatin-

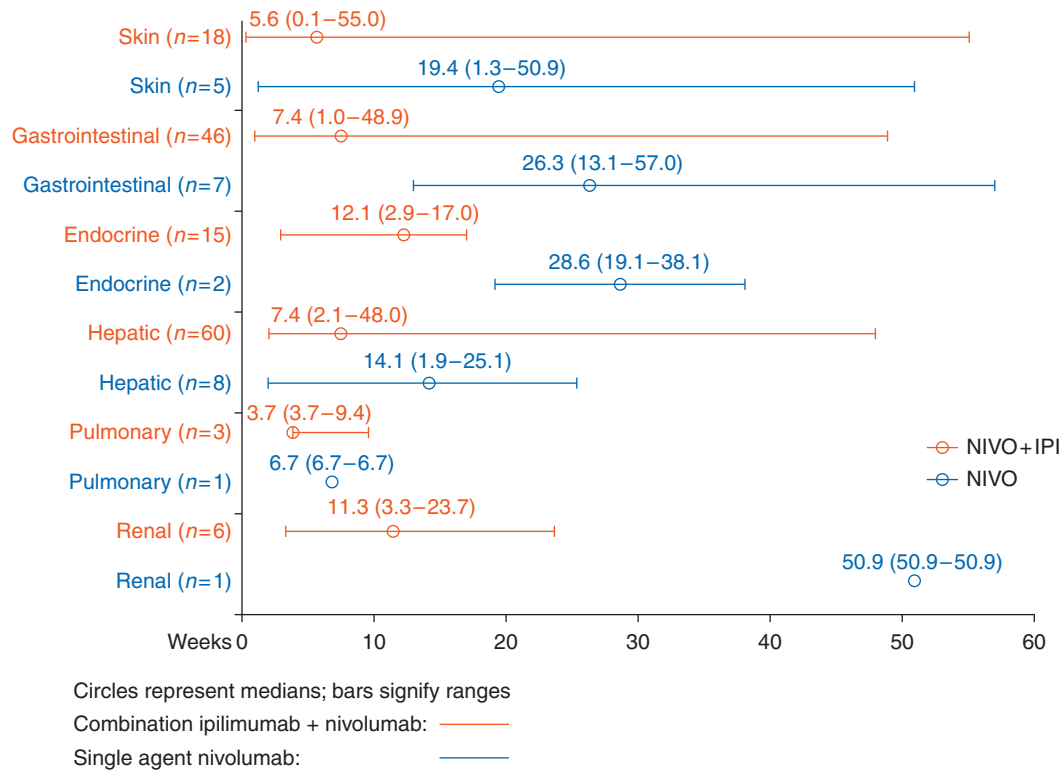


Figure 2. Time to onset of grade 3–4 treatment-related select AEs. AE, adverse event; IPI, ipilimumab; NIVO, nivolumab. Reprinted from [87] with permission.

based chemotherapy as first-line treatment in metastatic NSCLC patients (tumour PD-L1 expression $\geq 50\%$). Treatment-related toxicity was reported in 73.4% (any AE) and 26.6% of patients with a grade 3 or higher AE [14].

Combination of CTLA4 and PD-1/PD-L1 blockade immune-related toxicities

Combination immunotherapy has only been approved for patients with metastatic melanoma. Treatment-related AEs were observed in 95% of patients. In 55% of patients these AEs were of grade 3 or higher [2]. The onset of grade 3 to 4 toxicities for either monotherapy with nivolumab or combination immunotherapy differs, as irAEs not only may develop earlier in combination therapy but also may start over a prolonged period of time (Figure 2).

General aspects of irAEs

In general, irAEs occur quite early, mostly within weeks to 3 months after initiation of immune checkpoint blockers. However, the first onset of irAEs has been documented as long as 1 year after discontinuation of treatment.

The role of tissue biopsy in the diagnosis of immune-therapy related toxicity is not established. Some recommendations suggest tissue biopsy in higher grade (3 and 4) toxicity [skin, gastrointestinal (GI), liver, kidney, lung] where there is diagnostic doubt about the aetiology of the complication and management would be altered by the outcome of the biopsy procedure [15]. In

general, when biopsy is carried out in such circumstances, the reporting pathologist must be apprised of the specific reasons for the biopsy procedure.

Patient selection and baseline assessments

Before starting treatment, patients should be assessed in terms of susceptibility to develop irAEs. This includes a work-up consisting of patient history (and family history), general physical condition, autoimmune diseases, baseline laboratory tests and radiological exams (Supplementary Table S1, available at *Annals of Oncology* online) [mostly computed tomography (CT) scans of the chest, abdomen/pelvis and often brain magnetic resonance imaging (MRI)]. Patients with a history of autoimmune disease, or who are being actively treated for an autoimmune disease, are at risk for worsening of their autoimmune disease while on immune checkpoint blockade [16]. Similarly, patients that have had irAEs on ipilimumab are at risk of developing irAEs following anti-PD-1 treatment and vice versa [16, 17]. Results from these retrospective series showed a higher rate of grade 3 to 4 toxicity in patients treated with ipilimumab following anti-PD-1 (up to 35%) and patients with grade 3 to 4 toxicity on ipilimumab followed by anti-PD-1 developed grade 3 to 4 irAEs in >20% of cases. The time between last dose of first drug and initiation of the second drug, however, may be important, considering the long half-lives of these MoAbs.

Patients should be informed of the potential AEs of immunotherapy before treatment initiation. In all cases, patients should report directly to the treating physician or team (nurse, nurse

practitioner, physician). Once irAEs have developed, prompt work-up is required and action should be taken to prevent further aggravation of AEs. In many cases, especially the most severe, immunotherapy should be discontinued and immunosuppressive or immune modulating drugs including high-dose corticosteroids, and sometimes tumour necrosis factor alpha (TNF α) antagonists, mycophenolate or tacrolimus, are needed to overcome these toxicities, followed by careful tapering of immunosuppression. Long-term (>6 weeks) treatment with immunosuppressive drugs or use of infliximab increases the chance of opportunistic infections; therefore, pneumocystis prophylaxis should be considered according to local guidelines. Importantly, so far there is no evidence that the clinical outcome of patients on ICPis is affected by the use of immunosuppressive agents for the management of immune-related toxicities [7, 18].

Immune-related skin toxicity

Incidence

Skin AEs are among the most frequent AEs observed by patients treated with MoAbs inhibiting either immune checkpoints CTLA4 (ipilimumab in 43%–45% of the patients) or PD-1 (nivolumab and pembrolizumab in ~34%) [1, 3, 19, 20] and usually develop early in the course of treatment (within the first few weeks after initiation).

However, serious skin AEs are rare and do not usually require dose reductions or treatment discontinuation.

One immune-related skin AE, vitiligo, seems to be associated with good clinical responses to anti-PD-1 MoAbs in patients treated for melanoma [21].

The most frequent skin AEs are rash, pruritus and vitiligo, but the latter is seen mostly in patients treated for melanoma [20]. Rash is reported in ~24% of the patients treated with ipilimumab, in ~15% of those receiving anti-PD-1 MoAbs and in 40% with the combination of ipilimumab and nivolumab. However, grade 3 or 4 rashes are rare, with an incidence of <3% with monotherapy ipilimumab or anti-PD-1 and <5% with the combination [2, 22]. Pruritus is reported in around 25%–35% of the cases with ipilimumab, 13%–20% with anti-PD-1 and 33% with the combination, but reaches a grade 3 and 4 in <2.5% [22]. Vitiligo is reported in about 8% of patients with melanoma treated with anti-PD-1 MoAbs [20] or with the combination of checkpoint inhibitors, but is more rarely reported with ipilimumab alone. In a small prospective study, vitiligo was found in up to 25% of patients treated with pembrolizumab [21]. It is likely that the incidence is underreported in clinical trials, due to the fact that patients are not routinely seen and systematically subjected to a full-body skin exam by a dermatologist. In this study, the occurrence of vitiligo was significantly associated with the clinical response to the drug. Development of vitiligo is predominantly observed in melanoma patients treated with ICPis but not in NSCLC or renal cancer. More rarely, other skin AEs have been reported with checkpoint inhibitors: alopecia areata, stomatitis, xerosis cutis and photosensitivity. Exacerbation of psoriasis has also been anecdotally reported with these drugs, as well as psoriasiform

or lichenoid skin reactions in patients without any history of such skin disease [19, 23].

Histopathologically, skin reactions may be categorised into four broad groups [24]:

- Inflammatory skin disorders, which comprise a range of changes reflecting acute, subacute or chronic inflammation of various patterns, associated with variable epidermal changes, including psoriasiform or lichenoid reactions. A lichenoid interface chronic dermatitis is a common finding [25, 26];
- Immunobullous skin lesions akin to dermatitis herpetiformis or bullous pemphigoid;
- Keratinocyte alteration—Grover's disease [27]/acantholytic dyskeratosis;
- Immune-reaction mediated by alteration of melanocytes (regression of nevi, prurigo nodularis, tumoural melanosis and vitiligo).

Diagnosis and pathology/molecular biology

When a patient treated with a checkpoint inhibitor presents with a skin AE, the first requirement is ruling out any other aetiology of the skin problem, such as an infection, an effect of another drug or a skin condition linked to another systemic disease. Next, the severity of the skin AE needs to be evaluated by a careful and thorough physical examination of the skin including the mucosal areas, an appreciation of the general patient status (fever, enlarged lymph nodes etc.), and if needed, a biological checkup including a blood cell count, liver and kidney tests. This will help to eliminate the possibility of a dermatological emergency such as drug rash with eosinophilia and systemic symptoms (DRESS), acute febrile neutrophilic dermatosis (Sweet syndrome), Stevens-Johnson syndrome or toxic epidermal necrolysis (TEN). In such life-threatening cases (fatal cases have already been described), the treatment with checkpoint inhibitor(s) should be permanently discontinued, the patient should be hospitalised, and symptomatic treatment should be initiated immediately by a dermatologist or at a specialised dermatology unit.

To gauge the severity of the skin AE, the Common Terminology Criteria for Adverse Events (CTCAE) classification is usually used.

Concerning a maculopapular rash, the most frequent event with checkpoint inhibitors, the fourth version of the CTCAE classification proposes:

- Grade 1: macules/papules covering <10% the body surface area (BSA) with or without symptoms (e.g. pruritus, burning, tightness);
- Grade 2: macules/papules covering 10%–30% BSA with or without symptoms (e.g. pruritus, burning, tightness); limiting instrumental activities of daily living (ADL);
- Grade 3: macules/papules covering >30% BSA with or without associated symptoms; limiting selfcare ADL;
- Grade 4: papulopustular rash associated with life-threatening superinfection; Stevens-Johnson syndrome, TEN and bullous dermatitis covering >30% of BSA and requiring intensive care unit (ICU) admission.

The relation with impairment in instrumental or selfcare ADL seems appropriate to evaluate the severity of the AE as well as its impact on the patient's life. However, the fact that when >30% BSA is involved, the rash is automatically graded 3, is subject to

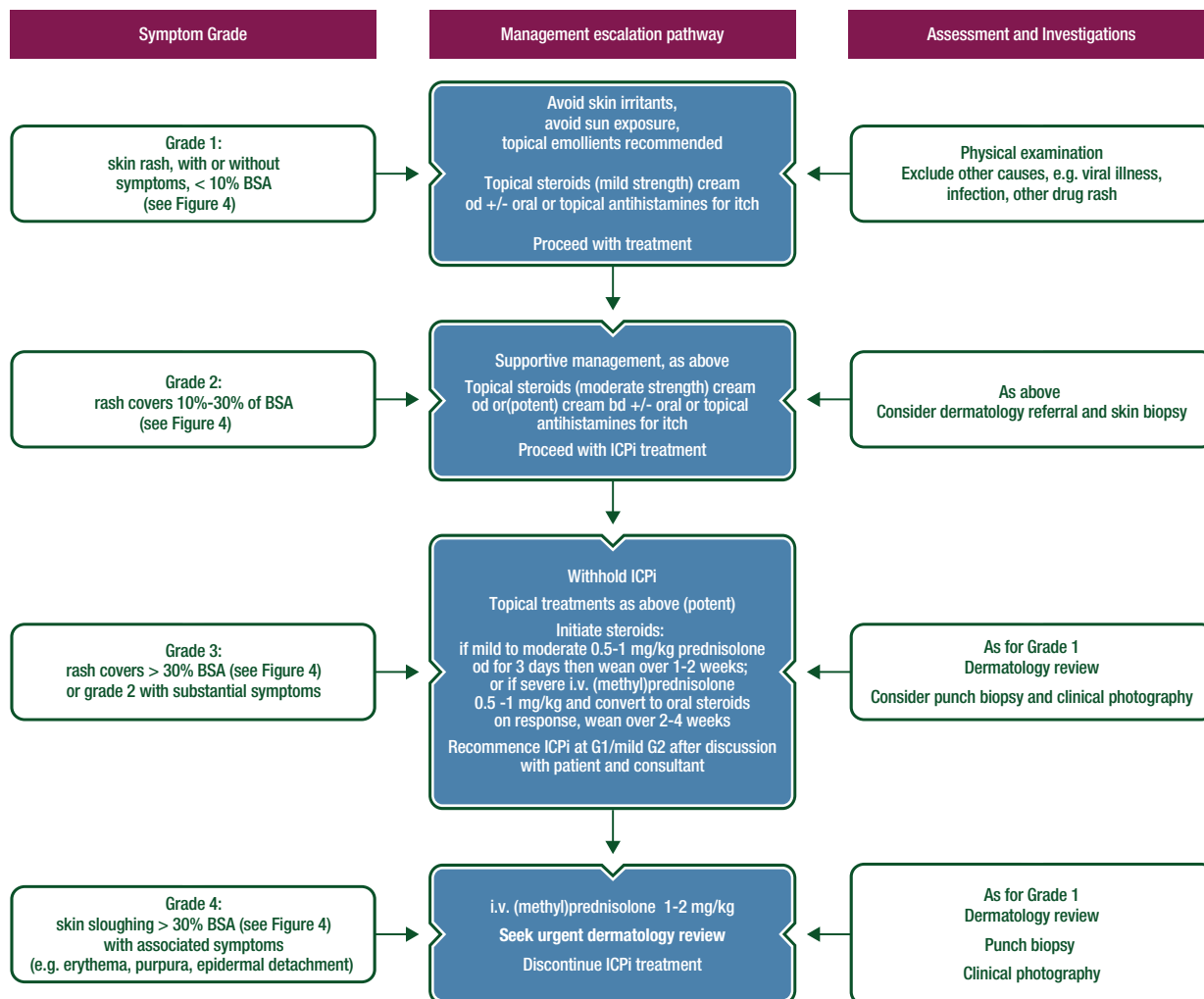


Figure 3. ICPI-related toxicity: management of skin rash/toxicity.

Recognised skin AEs include: (i) most common: erythema, maculopapular and pustulopapular rash; (ii) rare: toxic epidermal necrolysis, Steven-Johnson syndrome and DRESS; (iii) vasculitis may also be present with purpuric rash.

AE, adverse event; bd, twice daily; BSA, body surface area; DRESS, drug rash with eosinophilia and systemic symptoms; ICPI, immune checkpoint inhibitor; i.v., intravenous; od, once daily.

discussion. Indeed, when the rash is diffuse but light and not associated with any additional symptoms, a grade 2 would seem more appropriate than grade 3.

The fifth version of the CTCAE classification will give a more appropriate classification for skin AEs.

Management of rash

For grade 1 skin AEs such as rash and/or pruritus, treatment with checkpoint inhibitors can be continued (see Figures 3 and 4). Symptoms can be treated with topical emollients, oral antihistamines and/or mild strength topical corticosteroids. In the case of grade 2 skin AEs, treatment with checkpoint inhibitors can be continued but should be checked weekly for improvement. If not resolved, treatment should be interrupted until the skin AE has reverted to grade 1. Symptomatic treatment consists of topical emollients, oral antihistamines and median-to-high strength topical steroids. Grade 3 skin AEs also require immediate interruption of checkpoint inhibition, until these are back to grade 1.

Treatment includes topical emollients, oral antihistamines and high strength topical steroids [II, B]. Systemic corticosteroids 0.5–1 mg/kg can be considered, depending on the severity of the symptoms. In the rare event of grade 4 skin toxicity, treatment with checkpoint inhibitors should be interrupted, and patients should be admitted immediately and be placed under supervision of a dermatologist. Treatment consists of intravenous (i.v.) (methyl)prednisolone 1–2 mg/kg with tapering when the toxicity resolves to normal [II, B].

Immune-related endocrinopathies

Thyroid gland disorders

Although thyroid gland disorders have been observed quite frequently in patients treated with immunotherapies such as cytokines interleukin-2 and type I interferons, their incidence has increased

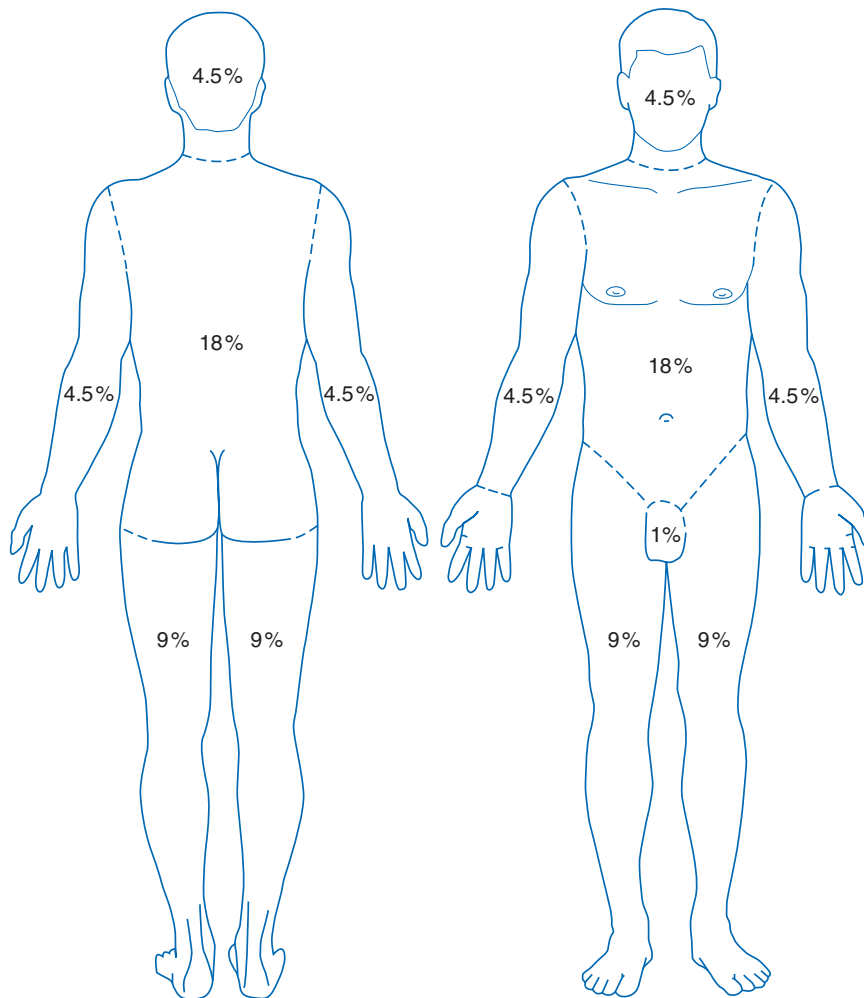


Figure 4. Schematic of body surface area (BSA).

considerably since the introduction of ICPis. Both hyper- and hypothyroidism have been reported, although hypothyroid disorders are more common than hyperthyroidism. The latter is often transient and may precede hypothyroidism. Still, little is known about the pathogenesis of thyroid disorders following ICPis. It is thought to be mediated by T cells and not by B cell autoimmunity. Recently, a cohort of 51 NSCLC patients treated with pembrolizumab in the Keynote-001 study was prospectively followed by thyroid-stimulating hormone (TSH), triiodothyronine and thyroxine (FT3, FT4) and anti-thyroid antibodies (Abs) measurement [28]. The incidence of thyroid dysfunction requiring thyroid hormone replacement was 21% (in 80% of these patients, anti-thyroid Abs were detected), compared with 8% in patients that did not develop thyroid dysfunction. These results suggest that the pathogenesis of autoimmune thyroid disease and thyroid gland dysfunction as irAEs might have a similar pathogenesis.

Thyroid dysfunction is most common upon treatment with anti-PD-1/PD-L1 or combination of anti-CTLA4 and agents blocking the PD-1/PD-L1 axis. With ipilimumab (3 mg/kg), the incidence was reported to be between 1% and 5% [1, 2], but higher incidence (up to 10%) has been observed with the higher doses of ipilimumab (10 mg/kg) [4].

With anti-PD-1 (either pembrolizumab or nivolumab) or anti-PD-L1 (atezolizumab) therapy, the reported thyroid dysfunction

rate varies from 5% to 10% (irrespective of tumour type) [6, 10, 12]. With combination immunotherapy (ipilimumab 3 mg/kg plus nivolumab 1 mg/kg), the frequency of thyroid disorders increases to 20% [2]. These events are rarely higher than grade 2. In most cases, thyroid dysfunction is found by routine blood tests (TSH and FT4); they should be carried out before every infusion or at least once a month (in the case of 2-weekly infusions).

Management

Even with subclinical hypothyroidism, substitution with thyroid hormone should be considered in the case of fatigue or other complaints that could be attributed to hypothyroidism [IV–V, B]. In symptomatic patients, especially in the case of hyperthyroidism, treatment with beta-blockers should be started (propranolol or atenolol) [IV–V, B]. Rarely, carbimazole or steroids are required. In those cases, treatment with ICPis should be interrupted until recovery from symptoms. Hormone replacement therapy (HRT) is usually long lasting (see Figure 5).

Hypophysitis

Before introduction of anti-CTLA4 therapy, hypophysitis, an inflammation of the anterior lobe of the pituitary gland, was extremely rare. Now, incidence rates of hypophysitis have been

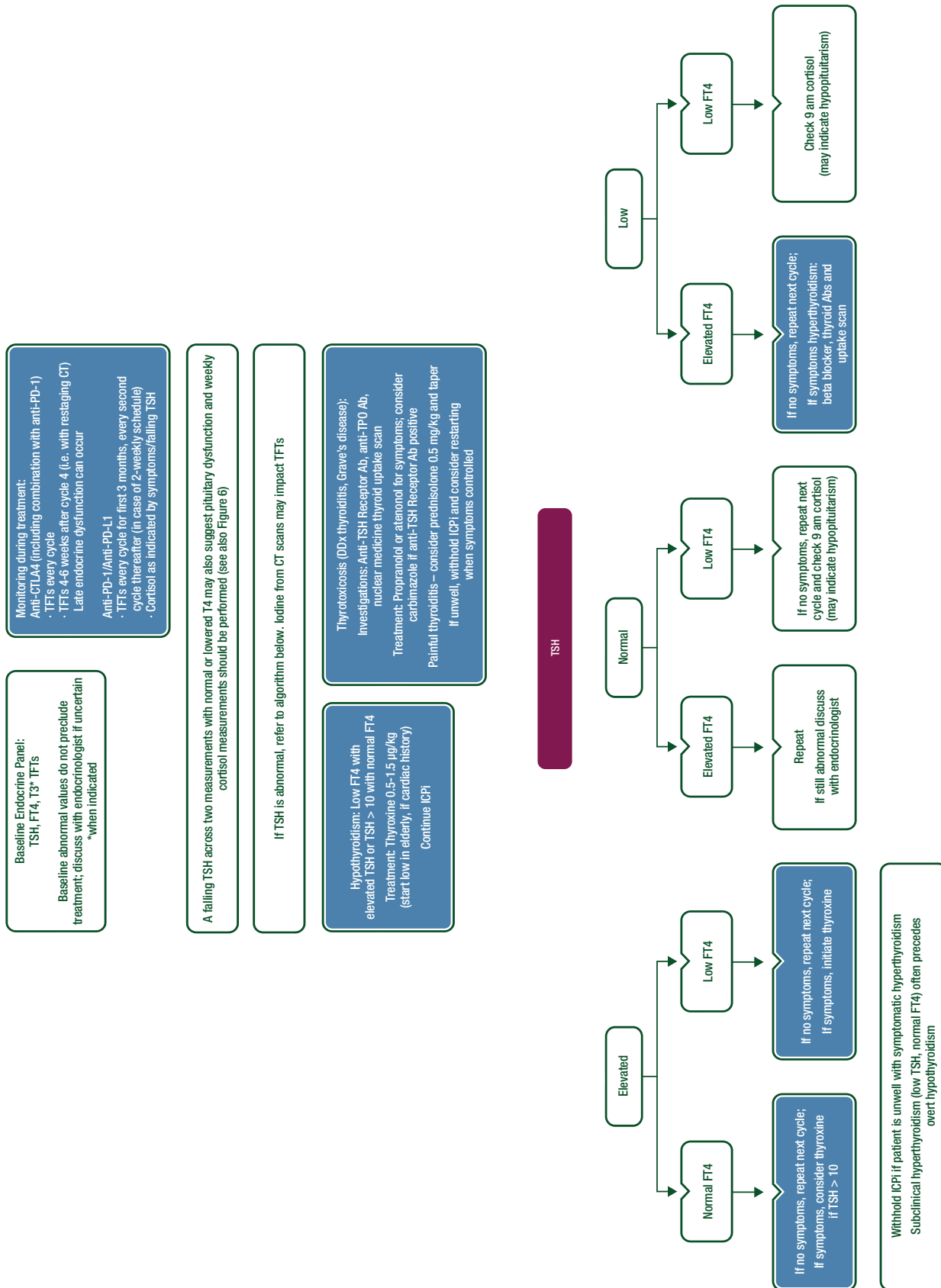


Figure 5. ICI monitoring and management: thyroid function. Ab, antibody; CT, computed tomography; CTLA4, cytotoxic T-lymphocyte associated antigen 4; DDx, differential diagnosis; FT4, free thyroxine; ICI, immune checkpoint inhibitor; PD-1, programmed death 1; PD-L1, programmed death ligand 1; T3, triiodothyronine; T4, thyroxine; TFTs, thyroid function tests; TPO, thyroid peroxidase; TSH, thyroid-stimulating hormone.

reported for ipilimumab 3 mg/kg, ipilimumab 10 mg/kg and the combination of ipilimumab and nivolumab in 1%, 16% and 8%, respectively [1, 2, 4].

Hypophysitis is very rare in patients treated with anti-PD-1 and anti-PD-L1 [29].

The aetiology of anti-CTLA4-induced hypophysitis remains unresolved. Recently, in a murine model, low-level ectopic RNA and protein expression of CTLA4 on thyrotropin and prolactin secreting cells of the pituitary gland [30] was demonstrated. So far, no explanation for this expression was found. Anti-CTLA4 treatment, however, led to mononuclear cell infiltration in the pituitary gland, anti-pituitary antibodies and activation of the complement cascade in these animals, causing inflammation of the gland, similar to what has been observed in full-blown hypophysitis in patients. Whether this ectopic CTLA4 expression occurs in human is unknown.

Patients may present with different complaints. Headache and visual disturbances require immediate evaluation and differentiation between cerebral metastasis, leptomeningeal disease, cerebrovascular disease and hypophysitis. On brain MRI, a swollen or enlarged pituitary gland may be visible. Frequently, simultaneous low blood levels of TSH, adrenocorticotropic hormone and/or follicle-stimulating hormone/luteinizing hormone (FSH/LH) point towards hypophysitis as the most likely diagnosis. Patients can present with hypothyroidism and/or hypocortisolism and with complaints relating to low testosterone levels.

Management

Once the diagnosis is confirmed, treatment with ICPis should be interrupted in any grade 2 or higher hypophysitis and treatment consisting of HRT should be instigated immediately [V, B]. In the case of headaches and other neurological problems, high-dose steroids should be given; however, high-dose steroids appear not to counteract the hormonal deficiency resulting from anti-CTLA4 treatment. In most cases, the immune checkpoint inhibition can be continued. Long-term HRT is required in most patients (see Figure 6).

Type 1 diabetes mellitus

De novo diabetes induced by treatment with ICPis occurs at low frequency (<1%). Diabetes mellitus (DM) appears to be more common with PD-1 and PD-L1 blockade (or combination immunotherapy) than with ipilimumab [31]. The PD-1 pathway plays a role in autoimmune DM as blockade of the PD-1/PD-L1 axis triggers the development of type 1 DM mediated by specific CD8 T cells in murine models. However, incidence of type 1 DM may rise as a consequence of treatment of larger patient populations with anti-PD-1 or anti-PD-L1 drugs.

It is recommended that blood glucose levels are regularly monitored in patients treated with ICPis in order to detect the emergence of DM. This could be either type 1 or type 2 DM. Even patients with type 2 DM may develop ketoacidosis, an infrequent but life-threatening event that should be treated according to standard local guidelines [I, A]. Whether treatment with high-dose steroids can prevent total loss of beta cells of the islands of Langerhans is unclear. Steroids will most likely negatively influence diabetes control in these patients.

C-peptide and Abs against glutamic acid decarboxylase (GAD) and islet cell (ICA) should be measured to distinguish between type 1 and type 2 DM.

Once the patient has been regulated with insulin substitution, restarting treatment with ICPis may be considered.

Immune-related hepatotoxicity

Incidence

Hepatitis occurs in 5%–10% (of which 1%–2% is grade 3) of patients during therapy with ipilimumab, nivolumab and pembrolizumab at the approved doses as single agents and in ~25%–30% (of which ~15% is grade 3) of those treated with the combination of ipilimumab 3 mg/kg and nivolumab 1 mg/kg [2, 12].

Diagnosis

All patients undergoing ICPi therapy should be assessed for signs and symptoms of hepatitis with serum transaminases and bilirubin measured before every cycle of treatment. Hepatitis is usually asymptomatic and detected on such routine blood monitoring. If hepatitis develops, disease-related causes, concomitant drug administration (including alcohol) and infectious causes, particularly viral hepatitis, should be ruled out. However, initiation of therapy, if needed, should not be delayed while awaiting serological results if there is no other apparent cause.

Liver biopsy may be considered in assisting in the differential diagnosis of more severe hepatic reactions [15]. Lobular hepatitis indistinguishable from autoimmune hepatitis is most commonly reported [32, 33]; most cases are panlobular but inflammation may be confined to zone 3. Additional sinusoidal histiocytosis and central vein endothelitis may help identify ipilimumab-associated inflammation. Rare cases show portal tract inflammation and cholangitis or changes indistinguishable from non-alcoholic steatohepatitis (NASH).

Management

In the event of moderate (grade 2) transaminase or total bilirubin elevation, checkpoint inhibitor therapy should be withheld and transaminases and bilirubin measured twice weekly. Persistent grade 2 elevation lasting longer than 1–2 weeks, after having ruled out other causes, should be treated with corticosteroids at a dose of 1 mg/kg/day (methyl)prednisolone or equivalent. Upon improvement, checkpoint inhibitor therapy may be resumed after corticosteroid tapering. If worsening or no improvement occurs despite initiation of corticosteroids, corticosteroid dose should be increased to 2 mg/kg/day (methyl)prednisolone or equivalent and checkpoint inhibitor therapy permanently discontinued [IV–V, B]. For grade 3 or 4 transaminase or total bilirubin elevation, checkpoint inhibitor therapy should be permanently discontinued, and corticosteroids started at 1–2 mg/kg/day (methyl)prednisolone or equivalent. If there is no response to corticosteroids within 2–3 days, mycophenolate mofetil should be added at 1000 mg twice daily [IV–V, B] [34]. Consultation with a hepatologist and consideration of liver biopsy (see above) is recommended in steroid and mycophenolate-refractory cases

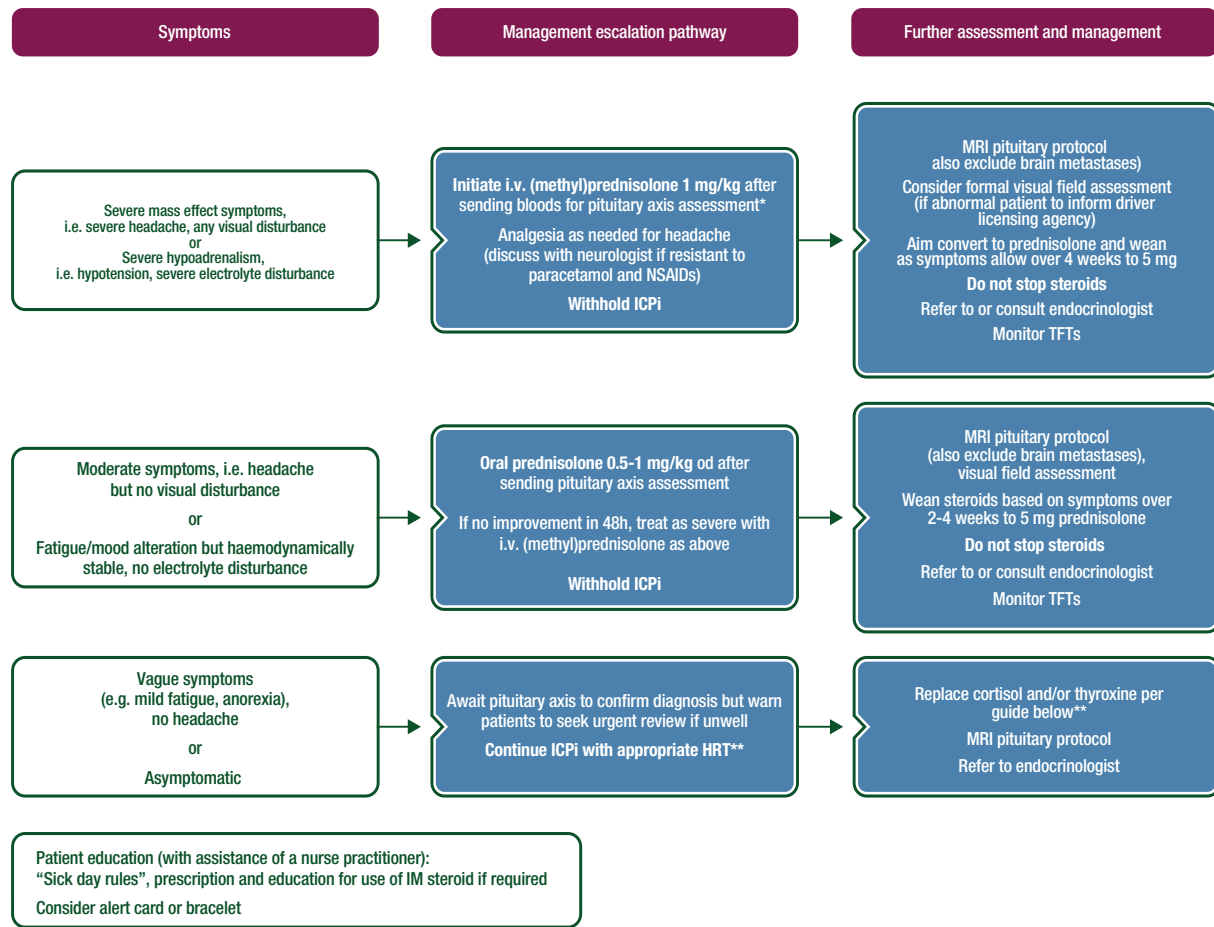


Figure 6. ICPI-related toxicity: management of hypophysitis.

*Pituitary Axis bloods: 9 am cortisol (or random if unwell and treatment cannot be delayed), ACTH, TSH/FT4, LH, FSH, oestradiol if premenopausal, testosterone in men, IGF-1, prolactin. Mineralocorticoids replacement is rarely necessary in hypopituitarism.

**Initial replacement advice for cortisol and thyroid hormones:

- If 9 am cortisol < 250 or random cortisol < 150 and vague symptoms:
 - Replace with hydrocortisone 20/10/10 mg
 - If TFTs normal, 1–2 weekly monitoring initially (always replace cortisol for 1 week prior to thyroxine initiation)
- If falling TSH +/- low FT4
 - Consider need for thyroxine replacement (guide is 0.5–1.5 µg/kg) based on symptoms +/- check 9 am weekly cortisol
 - See Thyroid Guidelines for further information regarding interpretation of an abnormal TSH/T4

ACTH, adrenocorticotropic hormone; FSH, follicle-stimulating hormone; FT4, free thyroxine; HRT, hormone replacement therapy; ICPI, immune checkpoint inhibitor; IGF-1, insulin-like growth factor-1; IM, intramuscular; i.v. intravenous; LH, luteinizing hormone; MRI, magnetic resonance imaging; NSAIDs, nonsteroidal anti-inflammatory drugs; od, once daily; TSH, thyroid-stimulating hormone; TFTs, thyroid function tests.

[IV–V, B]. Third-line immunosuppressive therapy is not well defined but the successful use of anti-thymocyte globulin (ATG) has been reported in a case of ipilimumab-induced hepatitis refractory to steroids and mycophenolate. Another third-line immunosuppressive therapy option is tacrolimus. Infliximab is not recommended for the treatment of immune-related hepatitis (see Figure 7).

Hepatitis usually resolves within 4–6 weeks with appropriate treatment but in the event that it does not resolve, other contributory causes should be reconsidered and the initial diagnostic work repeated as necessary, particularly bearing in mind the concomitant administration of other hepatotoxic drugs (including herbal medications and those purchased over the counter) and cytomegalovirus (CMV) reactivation.

Gastrointestinal toxicity

GI toxicity from cancer immunotherapy is well described for anti-CTLA4 Abs. It is less well described for anti-PD-1 and anti-PDL-1 Abs as well as for combined anti-CTLA4 and anti-PD-1 Abs.

Gastrointestinal toxicity of anti-CTLA4 antibodies

Incidence. Diarrhoea occurs in 27%–54% of cancer patients treated with anti-CTLA4 Abs [35]. In most series, approximately one-third of patients have diarrhoea, while the frequency of colitis ranges from 8% to 22% [35]. GI toxicity is one of the most frequent and is the most severe (grade 3 or higher) of irAEs associated with anti-CTLA4 [18]. It is usually the first irAE

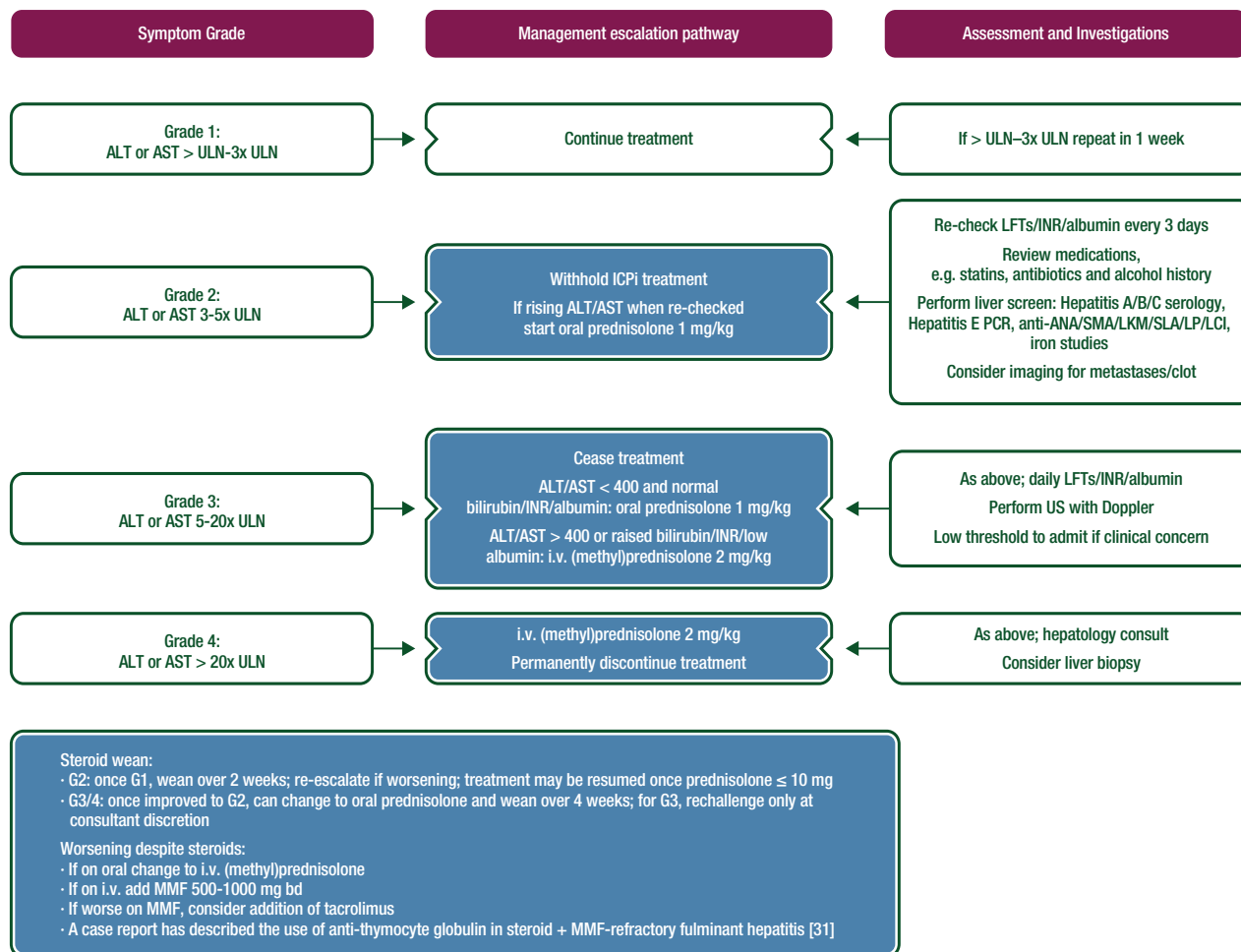


Figure 7. ICPI-related toxicity: management of hepatitis.

ALT, alanine transaminase; ANA, antinuclear antibodies; AST, aspartate transaminase; bd, twice daily; ICPI, immune checkpoint inhibitor; INR, international normalised ratio of prothrombin time; i.v. intravenous; LCI, lung clearance index; LFTs, liver function tests; LKM, liver kidney microsomal; MMF, mycophenolate mofetil; PCR, polymerase chain reaction; SLA/LP, soluble liver antigen/liver-pancreas antibody; SMA, smooth muscle autoantibody; ULN, upper limit of normal; US, ultrasound.

leading to anti-CTLA4 discontinuation [18]. Colon perforation occurred in 1%–1.5% of melanoma patients receiving ipilimumab [35–37]; it may reach 6.6% of patients with renal cell carcinoma [36], and 1.1% of patients die of complications related to ipilimumab-induced enterocolitis [4].

In a recent series, non-steroidal anti-inflammatory drug (NSAID) use was associated with an increased risk of anti-CTLA4-induced enterocolitis [38]. Very few data are available on the risk of immune-related colitis in patients with Crohn's disease (CD) and ulcerative colitis (UC). Two out of six patients with CD or UC had ipilimumab-induced colitis or a relapse of UC or CD [39].

Diagnosis. Onset of GI symptoms may occur at any time during 1-10 infusions of anti-CTLA4 [36]. Enterocolitis may even occur several months after the last dose of ipilimumab [40]. The half-life of ipilimumab is 2 weeks; however, the biological effect may persist long after drug clearance.

The most common symptom of anti-CTLA4-induced enterocolitis is diarrhoea [1–4]. In a recent series, 92% of patients with anti-CTLA4-induced enterocolitis had diarrhoea [38]. Other

presenting symptoms are abdominal pain, hematochezia, weight loss, fever and vomiting [38]. Mouth ulcers, anal lesions (fistulas, abscesses, fissures) and extra-intestinal manifestations (such as arthralgia, endocrine disorders, skin disorders, hepatitis, nephritis, pericarditis and pancreatitis) may be associated with anti-CTLA4-induced enterocolitis [38].

The main biological abnormalities observed in patients with anti-CTLA4-induced enterocolitis are anaemia, increased serum C-reactive protein and low serum albumin levels [38]. Faecal level of calprotectin has been found to be elevated in patients with ipilimumab-induced enterocolitis in one study [38] but failed to correlate with GI toxicity in another series [41]. Abs against the enteric flora and antineutrophil cytoplasmic Abs are found in the serum of a minority of patients with ipilimumab-induced enterocolitis [41].

The main differential diagnoses of anti-CTLA4 enterocolitis are GI infections and tumour-related symptoms. Stool analyses for bacterial enteropathogens and *Clostridium difficile* toxin should be carried out in every patient with significant diarrhoea treated with anti-CTLA4. In addition, GI metastases are not uncommon in patients with disseminated melanoma and are not

unknown in lung cancer; these should, therefore, be eliminated. Anti-CTLA4-induced enterocolitis should be confirmed by flexible sigmoidoscopy or colonoscopy with biopsies. Endoscopic lesions of anti-CTLA4 colitis are erythema/loss of vascular pattern, erosions and ulcerations. The sigmoid colon and the rectum are involved in most cases; therefore, a flexible sigmoidoscopy is generally sufficient to make the diagnosis of anti-CTLA4-induced enterocolitis [38]. However, endoscopic lesions of the colon are often extensive and may extend proximal to the sigmoid colon in two thirds of cases. Patchy discontinuous endoscopic lesions are observed in half of the patients [38]. The histological picture generally differs from that observed in inflammatory bowel disease (IBD). In most cases, it is that of an acute colitis (infiltration with neutrophils, eosinophils), either diffuse or focal with patchy crypt abscesses. In some cases, features of chronic IBD such as granulomas, basal plasmocytosis and crypt abnormalities (atrophy, distortion, branching, budding) have been reported [38].

Upper GI symptoms (dysphagia and epigastric pain) and endoscopic lesions (oesophageal ulcerations, gastritis,

duodenitis) have been reported [35, 38]. About half of the patients with anti-CTLA4-induced enterocolitis have chronic, mild, patchy inflammation of the stomach and the duodenum (crypt distortion, focal and heterogeneous villus shortening, increased eosinophils and mononuclear inflammatory cells in the lamina propria) [38].

Staging and risk assessment. Assessment of severity relies upon the National Cancer Institute's CTCAE, version 4. Severe diarrhoea refers to grade 3 or 4 diarrhoea but also to patients with grade 1 or 2 diarrhoea with dehydration, fever, tachycardia or haematochezia. Flexible sigmoidoscopy or colonoscopy is recommended in patients with severe diarrhoea or persistent grade 2 diarrhoea.

Management. Two randomised trials have failed to show any benefit from oral administration of budesonide, in an attempt to prevent occurrence of ipilimumab-induced enterocolitis [41, 42]. Patients with diarrhoea on anti-CTLA4 therapy should undergo a workup including complete blood count, serum electrolyte

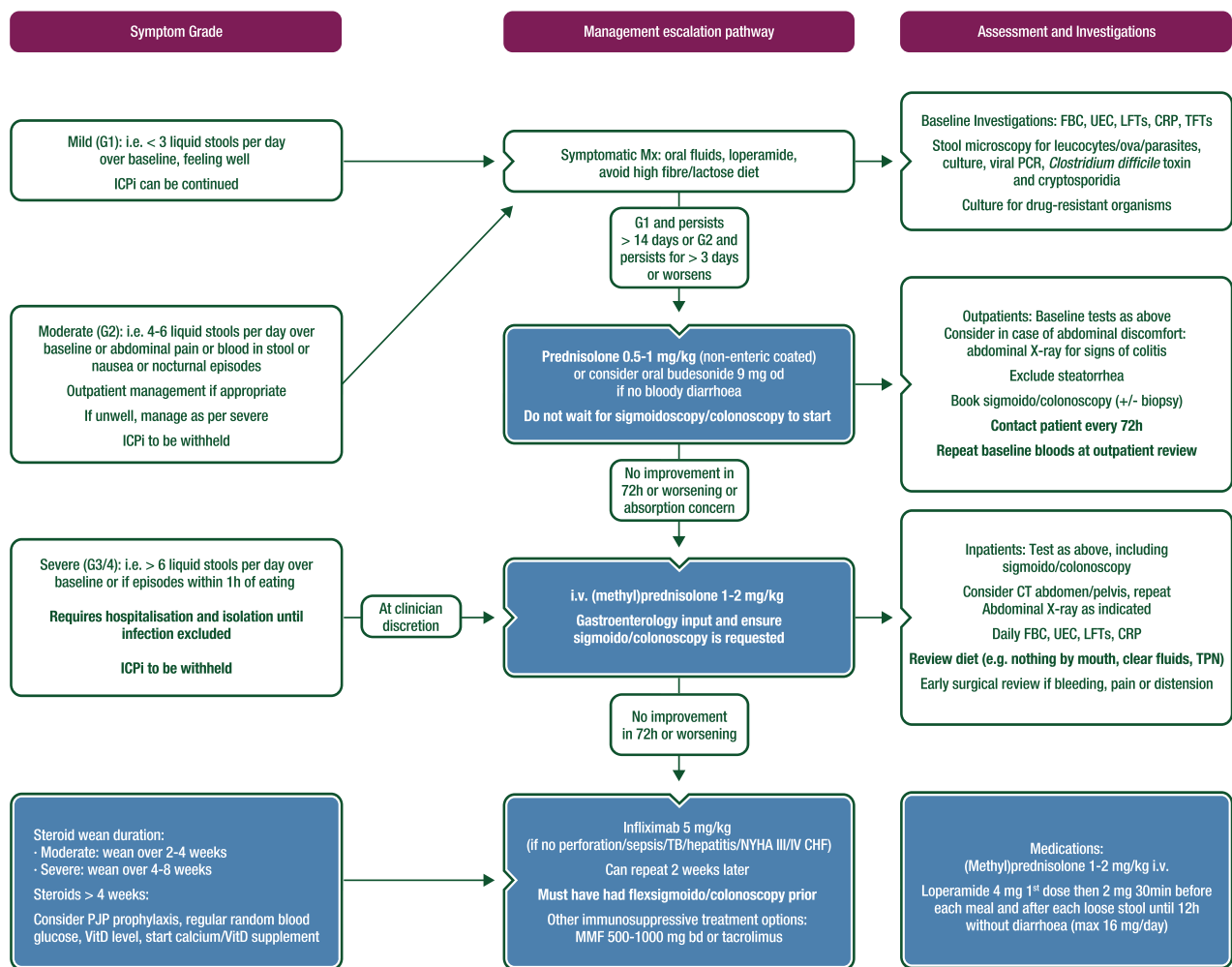


Figure 8. ICPI-related toxicity: management of diarrhoea and colitis.

bd, twice daily; CHF, congestive heart failure; CRP, C-reactive protein; CT, computed tomography; FBC, full blood count; ICPI, immune checkpoint inhibitor; i.v. intravenous; LFTs, liver function tests; MMF, mycophenolate mofetil; Mx, management; NYHA, New York Heart Association; od, once daily; PCR, polymerase chain reaction; PJP, Pneumocystis jiroveci pneumonia; TB, tuberculosis; TFTs, thyroid function tests; TPN, total parenteral nutrition; UEC, urea, electrolytes, creatinine; VitD, vitamin D.

profile, stool analyses for enteropathogens and *Clostridium difficile* toxin (see Figure 8).

Patients with non-severe diarrhoea should be treated with anti-diarrhoeals, fluid and electrolyte supplementation, if needed [IV–V, B] [35]. Anti-CTLA4 therapy can be continued. Patients with persistent grade 2 diarrhoea or severe diarrhoea (grade 3/4 diarrhoea, or grade 1/2 diarrhoea with alarm symptoms, as detailed above) should discontinue anti-CTLA4 therapy and receive systemic corticosteroids (1–2 mg/kg per day, i.v.) [IV–V, B]. Patients who have a response to i.v. corticosteroids within 3–5 days should be switched to the oral form and tapered over 8–12 weeks [35]. Patients who do not respond to corticosteroids within 3–5 days should be switched to infliximab, unless it is contraindicated [IV–V, B] (see Figure 8). Overall, one-third to two-thirds of patients either do not respond to high-dose i.v. steroids, or have a relapse requiring an increase in the corticosteroid dosage during the course of steroid tapering. These patients require infliximab and usually have an excellent response. A single dose of infliximab (5 mg/kg) is generally sufficient [18, 35, 36, 38]. Some patients may need a second dose of infliximab 2 weeks after the first administration.

Vedolizumab is a MoAb directed towards the integrin $\alpha_4\beta_7$. It inhibits the intestinal homing of T lymphocytes. Vedolizumab is a gut-specific immunosuppressive agent that is approved for UC and CD. A recent case series of seven patients with mild to moderate, steroid-dependent or steroid-refractory ipilimumab-induced enterocolitis has shown that six out of seven patients treated with vedolizumab went into remission; no AEs were reported with vedolizumab. This preliminary study suggests that vedolizumab is an alternative to infliximab [43]. Further studies are needed to confirm the efficacy and safety of vedolizumab in patients with ipilimumab-induced enterocolitis.

Recently, a colitis, possibly due to CMV reactivation, has been reported in a patient with medically refractory anti-CTLA4 colitis [44]. Further studies are needed to determine whether CMV plays a significant role in this setting.

Some patients develop a colonic perforation, with or without intra-abdominal abscess, either initially or during the course of medical treatment. They should have emergency colectomy. We recommend subtotal colectomy with ileostomy and sigmoidectomy because colonic lesions are generally extensive and segmental colonic resection is generally followed by a severe inflammation of the remaining colon in the postoperative phase [38].

Prediction of ipilimumab-related colitis. No routine biomarker has been found to predict ipilimumab-related colitis. Baseline microbiota composition may predict ipilimumab-induced colitis. More specifically, at baseline, an increased presence of bacteria belonging to the *Bacteroidetes* phylum species was found in patients who remained free of colitis after ipilimumab treatment [45]. A recent study has shown that distinct baseline gut microbiota composition is associated with colitis. Most of the baseline colitis-associated phylotypes were related to *Firmicutes* (e.g. relatives of *Faecalibacterium prausnitzii* and *Gemmiger formicilis*), whereas no colitis related phylotypes were assigned to *Bacteroidetes* [46].

Follow-up and long-term implications. Several studies have found associations between ipilimumab-induced enterocolitis and tumour regression or overall survival (OS) [36, 47]. However, in a dose

escalation study, higher serum levels and prolonged administration of anti-CTLA4 Abs resulted in a trend toward a greater incidence of grade 3/4 autoimmune toxicity, but did not seem to increase anti-cancer response rates [48].

Neither corticosteroids nor infliximab appear to affect response and OS of patients treated with ipilimumab [18, 47].

A study has shown that some patients have endoscopic or histological inflammation of the colon (including chronic inflammation) several months after the onset of enterocolitis [38]. In this study, three out of nine patients had chronic colitis on biopsies [38]. More studies are needed to determine whether the changes in these patients may evolve into chronic IBD.

In a recent study, four out of six patients who had an additional infusion of ipilimumab after going into enterocolitis remission relapsed [38]. Among them, three patients required a new steroid course, including one patient who had a severe steroid-refractory relapse requiring infliximab infusion. Reintroduction of anti-CTLA4 in patients, who had previously experienced enterocolitis, poses a high risk of relapse and should be discussed on an individual basis.

In a recent randomised trial that compared nivolumab followed by ipilimumab, or the reverse sequence, in patients with advanced melanoma, a severe AE with the first agent did not predict toxicity with the second one [49]. This was confirmed by a recent study, which showed that, among 47 patients who had an anti-CTLA4-induced colitis, only one relapsed under anti-PD-1 [49].

Gastrointestinal toxicity of anti-PD-1 antibodies

Very few data are available about GI irAEs associated with anti-PD-1 MoAbs. Diarrhoea and colitis are more frequent with anti-CTLA4 agents than with either nivolumab or pembrolizumab, with grade 3 to 4 AEs occurring in 1%–2% of cases [2, 50]. A case series of 19 patients with GI toxicity after anti-PD-1 Ab administration has been published [51]. The median time from drug initiation to symptom onset was 3 months. The most common symptom was diarrhoea, followed by nausea/vomiting and abdominal pain. Endoscopic findings consisted in normal mucosa or inflammation ranging from mild erythema to severe inflammation (mucosal friability or ulceration). Histological findings included lamina propria expansion, villus blunting, intra-epithelial neutrophils and increased crypt/gland apoptosis. Intra-epithelial lymphocytes were rarely prominent. A recent pathology study based upon eight cases has described two patterns: active colitis with neutrophilic crypt micro-abscesses and atrophy as well as crypt epithelial cell apoptosis ($n=5$) or lymphocytic colitis characterised by increased intraepithelial lymphocytes ($n=3$) [51]. A preliminary report confirmed and extended this description. It depicted four different patterns of GI irAEs induced by anti-PD-1 Abs: acute colitis similar to that induced by anti-CTLA4 Abs, microscopic colitis, upper GI involvement and pseudo-obstruction [52]. In this study, 87.5% of patients responded to corticosteroids.

Gastrointestinal toxicity of combined anti-CTLA4 and anti-PD-1 antibodies

Diarrhoea and colitis, including severe forms, occur earlier (Figure 2) and are more frequent with combined anti-CTLA4 and anti-PD-1 agents than with either ipilimumab [2, 53, 54] or anti-PD-1 [2]. Other GI toxicities may also occur, including

pancreatitis and small bowel enteritis, which may be visible on CT scan. These rare toxicities require discontinuation of ICPI treatment and initiation of immunosuppression treatment. There is a need for a more detailed description of GI irAEs associated with combined anti-CTLA4 anti-PD-1 Abs.

Immune-related pneumonitis

Pneumonitis associated with checkpoint blockade is a toxicity of variable onset and clinical, radiological and pathological appearances, which has been observed with anti-PD-1/PD-L1 MoAbs and, more rarely, with anti-CTLA4 MoAbs. It is more common when anti-PD-1/PD-L1 MoAbs are combined with anti-CTLA4 MoAbs. Several cases of distinct life-threatening respiratory events have been reported under anti-CTLA4 monotherapy. Acute interstitial pneumonitis/diffuse alveolar damage syndrome (DADS) is the most acute, life threatening event [55], but organising inflammatory pneumonia, as well as a sarcoidosis-like pulmonary granulomatosis have been described and may result in difficulties in differential diagnosis with progression of disease [56–58]. Rarely, pneumonitis worsens despite immunosuppression, and may be fatal due to infection or progressive disease.

Using treatment with anti-PD-1/PD-L1 MoAbs, respiratory events like cough and dyspnoea have been documented in up to 20%–40% of patients, with grade 3 to 4 cough in 2%–9% and grade 3 to 4 dyspnoea in 1%–2% of patients, respectively [59–61]. Documentation of pneumonitis occurs in 2%–4% of patients, with 1%–2% grade ≥ 3 events, frequency of fatal pneumonitis in 0.2% and discontinuation due to pneumonitis in 0.2%–4% [6, 7, 62–65]. In the absence of any direct comparison, to date there is no compelling evidence that this incidence might significantly differ between anti-PD-1 and anti-PD-L1 compounds [63].

Data documenting pulmonary immune-related toxicities have been progressively reported from retrospective series, from large published prospective trials and subsequent expanded access programs, especially in the treatment of melanoma, NSCLC and renal carcinoma. To date, however, immune-induced pneumonitis remains relatively poorly described.

Whereas pulmonary AEs are most often related to disease progression, particularly in the context of lung cancer or lung metastases, any new respiratory symptom should prompt a dedicated evaluation to formally exclude lung toxicity. All patients presenting with pulmonary symptoms, such as an upper respiratory infection, new cough, shortness of breath or hypoxia should be assessed by CT. Any respiratory symptom or sign must be carefully monitored, since fatal and life-threatening cases of pneumonitis have been reported.

Incidence

The incidence of pneumonitis is higher—possibly 1.5–2 times more frequent, in patients receiving anti-PD-1 therapy compared with ipilimumab monotherapy, as reported across several melanoma trials [12].

The combination of anti-PD-1/PD-L1 MoAbs with CTLA4 inhibition significantly increases the risk of pneumonitis, with up to

3 times more all-grade and grade ≥ 3 events compared with monotherapy reported in a 3-arm randomised melanoma trial [2].

Incidence of pneumonitis was recently reported in a multi-centre large retrospective analysis of patients receiving anti-PD-1/PD-L1 monotherapy or in combination with anti-CTLA4, as diagnosed by the treating investigator after exclusion of a tumoural or infectious aetiology [66]. Of 915 patients who received anti-PD-1/PD-L1 MoAbs, pneumonitis developed in 4.6%. Time to onset of pneumonitis ranged from 9 days to 19.2 months, with a median time to onset of 2.8 months, and tended to occur earlier in patients receiving combination therapy (2.7 versus 4.6 months). The incidence of pneumonitis was higher with combination immunotherapy versus monotherapy (10% versus 3%). Incidence was similar in patients with melanoma and NSCLC (5% versus 4%) overall, in monotherapy (3.6 versus 3.3%) and combination therapy (9.6% versus 7%). Of these, 72% were grade 1 to 2, and 86% improved or resolved with drug withholding and immunosuppression. Pneumonitis occurred irrespective of the line of therapy in which immunotherapy was received.

Although it may be observed at any time, pneumonitis tends to occur later than other irAEs, commonly some months after treatment was initiated. The rate of grade 3 to 4 pneumonitis is similar across tumour types and irrespective of dosage; however, there have been more treatment-related deaths due to pneumonitis in patients with NSCLC [13, 67]. Of note, detection, diagnosis and management of such symptoms have largely improved over time, and related mortality has been significantly reduced, making pooled analysis difficult to be interpreted in this context.

Importantly, radiological features of pneumonitis are not pathognomonic, and can include ground glass opacities, a cryptogenic organising pneumonia-like appearance and interstitial pneumonia pattern [55, 66, 68], as well as characteristics of hypersensitivity pneumonitis.

In general, lung biopsy is not required for subsequent patient management. However, if there is radiological or clinical doubt as to the aetiology of pulmonary infiltrates, then biopsy may provide an answer. It may assist in discriminating acute infection, or lepidic or lymphangitic spread of NSCLC, from a variety of inflammatory changes described above. If not apparent clinically, identification of DADS may be useful in terms of treatment and prognostication. Other patterns of lung reaction attributed to immunotherapy are not specific and reflect a range of chronic inflammatory, presumably immune-related processes, giving rise to changes such as non-specific interstitial pneumonitis, sarcoid-like [69] or hypersensitivity pneumonitis-like changes and organising pneumonia pattern of changes. All of these may be seen in other drug toxicities or in non-drug-related scenarios. While transbronchial lung biopsy may secure a diagnosis of infection or malignancy, and perhaps granulomatous disease or organising pneumonia, a surgical lung biopsy using video-assisted thoracoscopic surgery is more likely to secure a specific diagnosis. The decision to proceed with biopsy, and choice of technique, will depend on the location and distribution of disease on imaging, the availability of a thoracic surgical intervention team and any specific risks to the patient. If a biopsy is taken, it is vital that the reporting pathologist is informed about the background to, and reason for, the diagnostic procedure.

Alternatively, depending on the radiological pattern on CT scan, a bronchoscopy with bronchoalveolar lavage will support

the identification of infections, including potential opportunistic or atypical agents, and is recommended in any symptomatic pneumonia.

Management

In the case of documented or high suspicion of immune-related pneumonitis, immunosuppressive treatment should be started immediately. Ideally, an infection should be ruled out by bronchoscopy, especially in the case of grade ≥ 2 pneumonitis, in order to be able to safely introduce the immunosuppressive treatment. If the infectious status cannot be reliably assessed, most

algorithms advocate the administration of oral or i.v. broad spectrum antibiotics in parallel to the immunosuppressive treatment in grade ≥ 3 pneumonitis (see Figure 9).

In grade 1 to 2 pneumonitis, treatment consists of oral steroids with prednisone 1 mg/kg daily or equivalent [IV–V, B]. Patients should be clinically assessed every 2–3 days initially and, ideally, also radiologically in grade 2 pneumonitis. Steroids should be tapered over 4–6 weeks after recovery and reintroduction of the checkpoint inhibitor should be delayed until the daily dose of steroids equals 10 mg of oral prednisone per day or less.

In grade 3 to 4 moderate to severe cases, the patient should be hospitalised and treatment should consist of high-dose i.v.

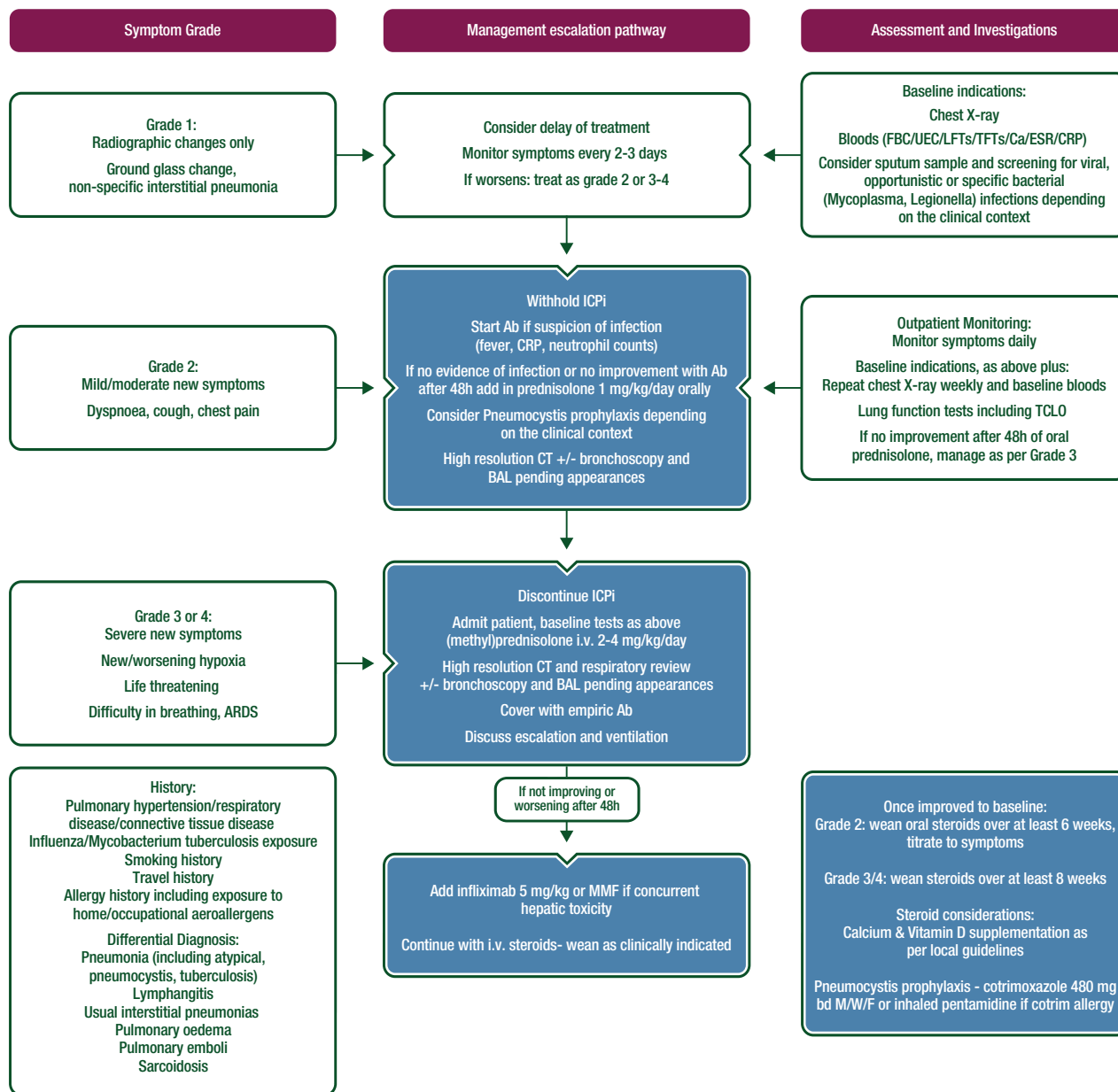


Figure 9. ICPI-related toxicity: management of pneumonitis.

Ab, antibody; ARDS, acute respiratory distress syndrome; BAL, bronchoalveolar lavage; bd M/W/F, twice daily Monday/Wednesday/Friday; Ca, calcium; CRP, C-reactive protein; CT, computed tomography; ESR, erythrocyte sedimentation rate; FBC, full blood count; ICPI, immune checkpoint inhibitor; i.v., intravenous; LFT, liver function tests; MMF, mycophenolate mofetil; TLCLO, transfer factor for carbon monoxide; TFT, thyroid function tests; UEC, urea, electrolytes, creatinine.

corticosteroids [(methyl)prednisolone 2–4 mg/kg/day or equivalent], and immunotherapy treatment permanently discontinued [IV–V, B]. Where the patient's condition does not improve or there is no imaging improvement after 2 days, additional immunosuppressive strategies should be implemented [55, 70, 71]. The addition of infliximab, mycophenolate mofetil (MMF) or cyclophosphamide are possible options. Tapering of steroids should be very slow and careful, over 6 weeks or more; relapses of pneumonitis during steroid tapering have been reported, adding considerations about recurrence in patients who rechallenge immunotherapy [66].

Rare-immune related toxicities

Neurological toxicity

The incidence of neuro-related AEs is reported as 1%. However, a recent analysis of 59 trials, involving 9208 patients reported a higher incidence: 3.8% in patients receiving anti-CTLA4, 6.1% in patients receiving anti-PD-1 agents and 12% in patients receiving anti-CTLA4 in combination with anti-PD-1 drugs. The time to onset varied from 6 to 13 weeks. A range of neurological events have been described, including polyneuropathy, facial nerve palsy, demyelination, myasthenia gravis, Guillain Barré syndrome, posterior reversible leukoencephalopathy, transverse myelitis, enteric neuropathy, encephalitis and aseptic meningitis. It is important to rule out progression of the underlying cancer, seizure activity, infection and metabolic derangement as causes of neurological impairment. Depending on the clinical presentation and imaging of the central nervous system, nerve conduction studies and lumbar puncture may assist in diagnosis. Early consultation with a neurologist is advised.

For all but mild (grade 1) neurological symptoms, checkpoint inhibitor therapy should be withheld until the nature of the AE is defined [V, B]. In the case of moderate symptoms prednisolone 0.5–1 mg/kg should be considered. High-dose steroid therapy with oral prednisolone (1–2 mg/kg) or i.v. equivalent should be used in the event of significant neurological toxicity [V, B]. Additionally, plasmapheresis or i.v. immunoglobulin (Ig) may be required in the treatment of myasthenia and Guillain Barré syndrome [V, B] (see Figures 10–12).

Cardiac toxicity

The incidence of cardiac AEs is <1%, but a wide range of toxicities including myocarditis, pericarditis, arrhythmias, cardiomyopathy and impaired ventricular function have been reported after treatment with ipilimumab, pembrolizumab and nivolumab [72–75]. However, the incidence of cardiac toxicity is higher with the combination of ipilimumab and nivolumab (0.27%) compared with nivolumab alone (0.06%). Early consultation with a cardiologist is recommended [V, B]. High-dose corticosteroids have been used successfully to treat cardiac side-effects and should be instituted rapidly if checkpoint inhibitor induced cardiac AEs are suspected. Escalation to other immunosuppressive drugs, such as infliximab, MMF and ATG, may be necessary if symptoms do not promptly respond to steroids [V, B].

Rheumatological toxicity

Mild or moderate myalgias and arthralgias occur in 2%–12% of patients and are more common with anti-PD-1 agents [76]. Vasculitis, polymyositis, myositis and temporal arteritis have also been described [73]. For mild or moderate symptoms, analgesia with paracetamol and/or NSAIDs is recommended [V, B]. In addition, moderate symptoms may respond to prednisolone at a dose of 10–20 mg/day or equivalent. Severe symptoms should prompt consultation with a rheumatologist and consideration of the use of high-dose corticosteroids and TNF α -blocking agents [V, B] (see Figure 13).

Renal toxicity

Renal dysfunction is rare with ipilimumab and with anti-PD-1 therapies, occurring in <1% of treated patients [77]. The incidence is much higher with combination of ipilimumab plus nivolumab, reaching 4.9%, with 1.7% of grade 3 to 4 toxicity. Similarly, sequential therapy with ipilimumab followed by nivolumab is associated with a high incidence of 5.1%, of which 2.2% of cases developed grade 3 to 4 nephritis [78]. Serum sodium, potassium, creatinine and urea should be measured before every infusion of checkpoint inhibitor and derangement of renal function managed initially by stopping nephrotoxic drugs (including over the counter medications), ruling out infection, urinary tract obstruction and correcting hypovolaemia. Checkpoint inhibitor therapy should be withheld in the event of significant renal dysfunction and consideration given to the use of systemic corticosteroid therapy [0.5–2 mg (methyl)prednisolone or equivalent] [V, B]. In the event of severe renal dysfunction, a nephrologist should be consulted. Renal biopsy may be used to clarify a difficult differential diagnosis [V, B]. In one series of patients who were biopsied after developing acute kidney injury while on ICPis an acute tubulo-interstitial nephritis with lymphocytic infiltration was the most frequent finding [79]. Recently, a severe case of antineutrophil cytoplasmic antibody-associated rapid progressive glomerulonephritis was described in a patient with thymic epithelial carcinoma on pembrolizumab treatment [80]. In keeping with pathology described in other organs, granulomatous changes were seen in about a quarter of patients and one had thrombotic microangiopathy (see Figure 14).

Ocular toxicities

irAEs of the eye are rare and occur in <1% of patients treated with ICPis [81]. These AEs can be divided into ocular inflammation, such as peripheral ulcerative keratitis, uveitis and Vogt–Koyanagi–Harada syndrome, orbital inflammation, including thyroid-associated orbitopathy and idiopathic orbital inflammation (scleritis, myositis, neuritis, dacryadenitis) and retinal and choroidal disease (choroidal neovascularisation and melanoma-associated retinopathy). Treatment of these rare toxicities depends on their severity, with topical corticosteroids in the case of episcleritis and anterior uveitis, and systemic corticosteroids in the case of severe ocular inflammation and orbital inflammation. Intravitreal anti-vascular endothelial growth factor (VEGF) is indicated for choroidal neovascularisation.

Haematological toxicities

Immune-related haematological AEs have rarely been described in patients treated with ICPI and do seem to occur. So far, lethal aplastic anaemia, autoimmune haemolytic anaemia and immune thrombocytopenic purpura have been described [82–84]. The optimal treatment of these often severe AEs is unknown. Initiation of high-dose corticosteroids and other immunosuppressive drugs should be carried out in close collaboration with a haematologist.

Allograft rejection

The limited literature suggests that ipilimumab as a single agent may be administered without necessarily causing rejection of cardiac, renal and liver allografts. However, several recent case reports have documented the risk of acute allograft rejection after anti-PD-1 therapy [85]. As such, this very significant risk must be

considered in discussing systemic therapy options in patients that might potentially benefit from anti-PD-1 therapy but who have allografted organs.

Methodology

These Clinical Practice Guidelines were developed in accordance with the ESMO standard operating procedures for Clinical Practice Guidelines development www.esmo.org/Guidelines/ESMO-Guidelines-Methodology. The relevant literature has been selected by the expert authors. A summary of recommendations is shown in Table 2. Levels of evidence and grades of recommendation have been applied using the system shown in Table 3. Statements without grading were considered justified standard clinical practice by the experts and the ESMO Faculty. This manuscript has been subjected to an anonymous peer review process.

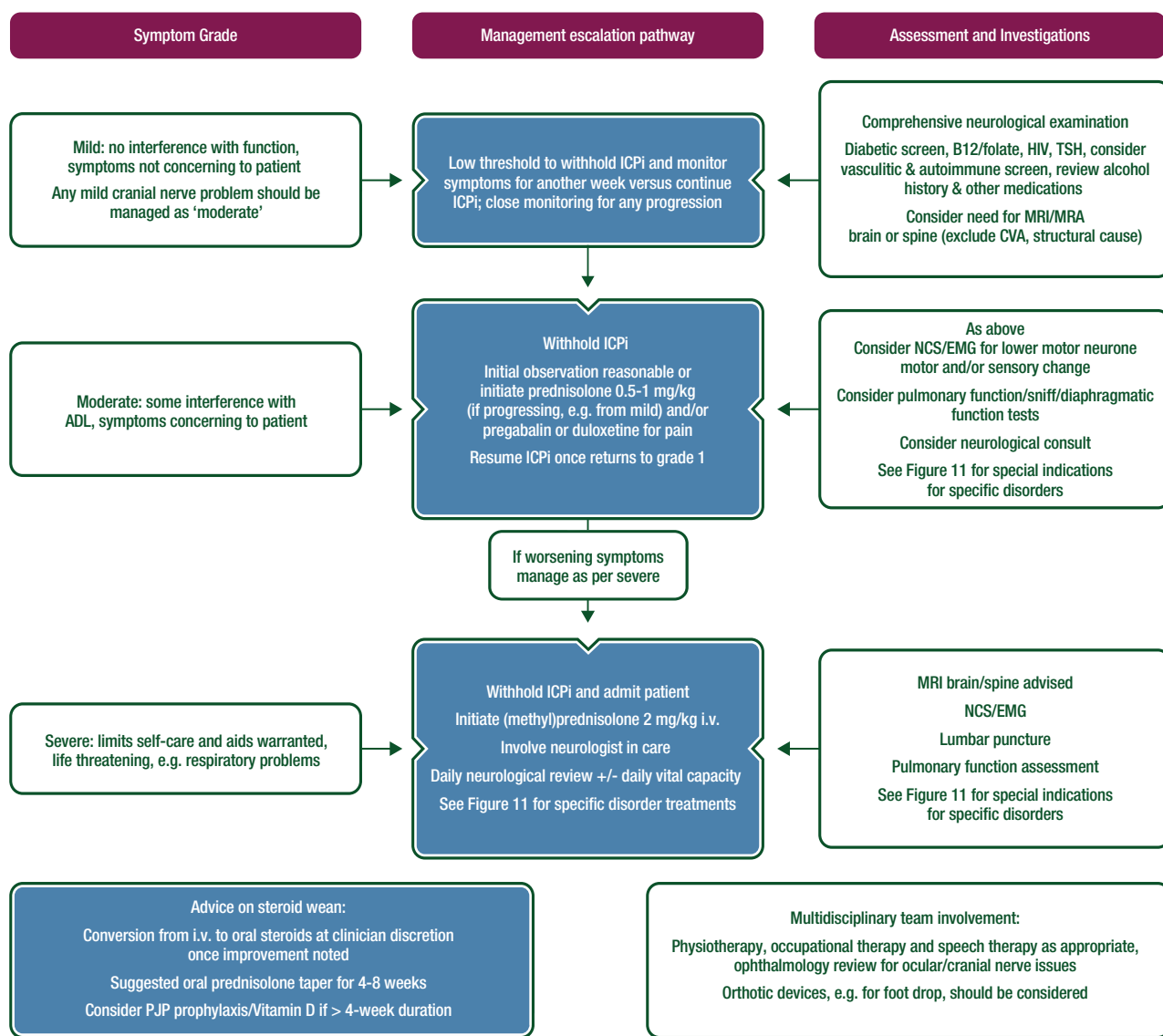


Figure 10. ICPI-related toxicity: management of suspected peripheral neurological toxicity.

ADL, activities of daily living; CVA, cerebrovascular accident; HIV, human immunodeficiency virus; ICPI, immune checkpoint inhibitor; i.v. intra-venous; MRA, magnetic resonance angiogram; MRI, magnetic resonance imaging; NCS/EMG, nerve conduction studies/electromyography; PJP, Pneumocystis jiroveci pneumonia; TSH, thyroid-stimulating hormone.

Suspected syndrome	Suggested Investigations	Management approach
<p>Guillain-Barré syndrome: Progressive symmetrical muscle weakness with absent or reduced tendon reflexes – involves extremities, facial, respiratory and bulbar and oculomotor muscles; dysregulation of autonomic nerves</p>	<p>Nerve conduction studies (acute polyneuropathy) Lumbar puncture (elevated protein with normal WBC count) Pulmonary function tests with vital capacity and maximum inspiratory/expiratory pressures Antibody testing for GBS variants, e.g. GQ1b in Miller Fisher variant</p>	<p>Use of steroids not recommended in idiopathic GBS; however, trial of (methyl)prednisolone 1–2 mg/kg reasonable Neurological consult If no improvement or worsening, plasmapheresis or IVIG indicated Consider location of care where ventilatory support available (required in 15%–30% idiopathic cases)</p>
<p>Myasthenia Gravis: Fluctuating muscle weakness (proximal limb, trunk, ocular, e.g. ptosis/diplopia or bulbar) with fatigability, respiratory muscles may also be involved</p>	<p>Check for ocular muscle and proximal muscle fatigability AChR and anti-MuSK antibodies Bedside tests, e.g. Tensilon test or ice pack test with neurological input Repetitive nerve stimulation and single fibre EMG</p>	<p>Steroids indicated (oral or i.v. depending on symptoms) Pyridostigmine initial dose 30 mg tds Neurological consult If no improvement or worsening, plasmapheresis or IVIG may be considered Additional immunosuppressants azathioprine, cyclosporine, mycophenolate Avoid certain medications, e.g. ciprofloxacin, beta-blockers, that may precipitate cholinergic crisis</p>
<p>Motor and sensory peripheral neuropathy, multifocal radicular neuropathy/plexopathy, autonomic neuropathy, phrenic nerve palsy, cranial nerve palsies (e.g. facial nerve, optic nerve, hypoglossal nerve) Steroids suggested as initial management where indicated with neurology specialist input and close attention to potential for respiratory or visual compromise</p>		

Figure 11. ICPI-related toxicity: management of suspected peripheral neurological toxicity. AChR, acetylcholine receptor; EMG, electromyography; GBS, Guillain-Barré syndrome; ICPI, immune checkpoint inhibitor; i.v., intravenous; IVIG, intravenous immunoglobulin; MuSK, muscle specific kinase; tds, three times a day; WBC, white blood cell.

Suspected syndrome	Suggested Investigations	Management approach
<p>Aseptic meningitis: Exclusion of infective causes paramount</p> <p>Headache, photophobia, neck stiffness with fever or may be afebrile, vomiting; normal cognition/cerebral function (distinguishes from encephalitis)</p>	<p>Lumbar puncture- M/C/S (normal Gram stain, WBCs < 500/μL, normal glucose), PCR for HSV, cytology</p> <p>CNS imaging to exclude brain metastases and leptomeningeal disease</p>	<p>Exclude bacterial and ideally viral infections prior to high-dose steroids</p> <p>Oral prednisolone 0.5-1 mg/kg or i.v. (methyl)prednisolone 1-2 mg/kg if very unwell</p> <p>Consider concurrent empiric antiviral (i.v. acyclovir) and antibacterial therapy</p>
<p>Encephalitis: Exclusion of infective and metabolic causes paramount</p> <p>Confusion or altered behaviour, headaches, alteration in Glasgow Coma Scale, motor or sensory deficits, speech abnormality, may or may not be febrile</p>	<p>Lumbar puncture- M/C/S (normal Gram stain, WBCs usually < 250/mm^3 with lymphocyte predominance, elevated protein but < 150 mg/dL, usually normal glucose but can be elevated), PCR for HSV & consider viral culture, cytology</p> <p>CNS imaging</p> <p>Consider viral serology</p>	<p>As above for aseptic meningitis</p> <p>Suggest concurrent i.v. acyclovir until PCR result obtained</p>
<p>Transverse myelitis: Acute or subacute neurological signs/symptoms of motor/sensory/autonomic origin; most have sensory level; often bilateral symptoms</p>	<p>MRI brain and spine</p> <p>Lumbar puncture – may be normal but lymphocytosis, elevated protein may be noted, oligoclonal bands not usually present, cytology</p> <p>Serum B12/HIV/syphilis/ANA/anti-Ro and anti-La Abs, TSH, anti-aquaporin-4 IgG</p>	<p>(Methyl)prednisolone 2 mg/kg (or consider 1 g/day)</p> <p>Neurology consultation</p> <p>Plasmapheresis may be required if non-steroid responsive</p>
<p>Neurosarcoidosis, Posterior Reversible Leucoencephalopathy Syndrome (PRES), Vogt-Harada-Koyanagi syndrome, Neurosarcoidosis, demyelination, vasculitic encephalopathy, generalised seizures</p> <p>Other syndromes reported:</p>		

Figure 12. ICPI-related toxicity: management of suspected central neurological toxicity.

Abs, antibodies; ANA, antinuclear antibody; CNS, central nervous system; HIV, human immunodeficiency virus; HSV, Herpes simplex virus; ICPI, immune checkpoint inhibitor; IgG, immunoglobulin G; i.v., intravenous; M/C/S, microscopy, culture and susceptibility; MRI, magnetic resonance imaging; PCR, polymerase chain reaction; TSH, thyroid-stimulating hormone; WBCs, white blood cells.

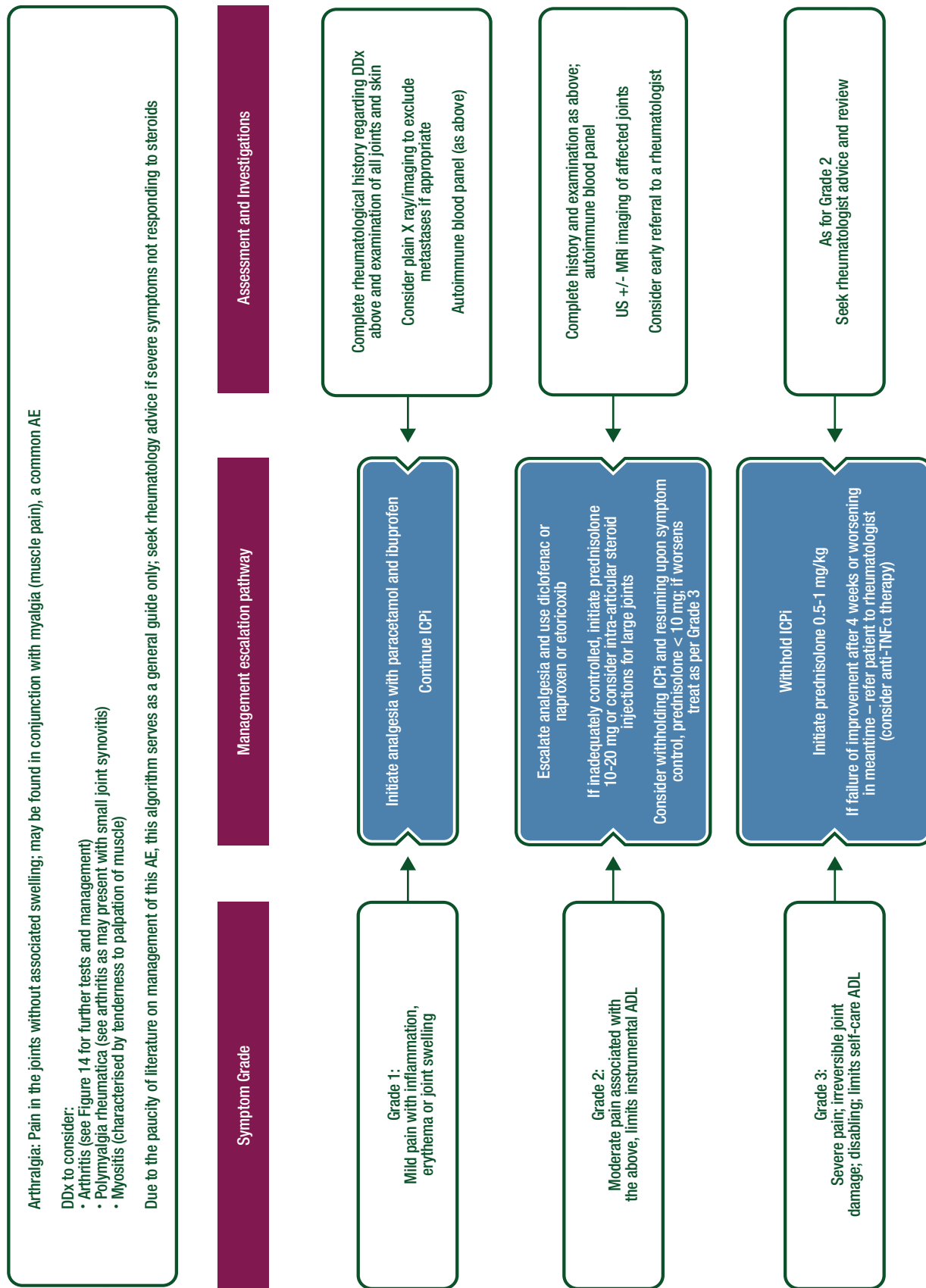


Figure 13. ICPI-related toxicity: management of arthralgia.

ADL, activities of daily living; AE, adverse event; DDx, differential diagnosis; ICPI, immune checkpoint inhibitor; MRI, magnetic resonance imaging; TNF α , tumour necrosis factor alpha; US, ultrasound.

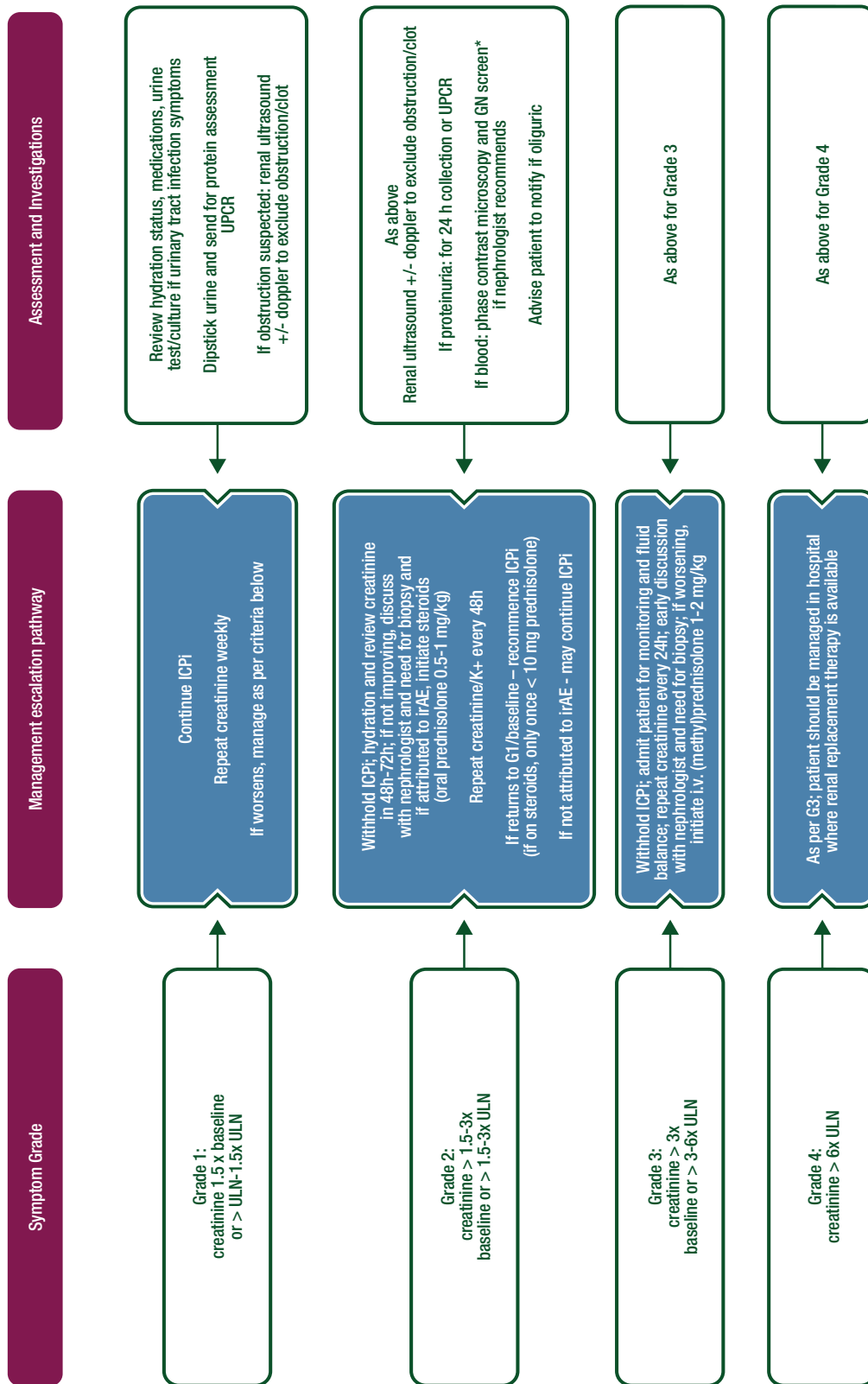


Figure 14. ICPi-related toxicity: management of nephritis.

Renal injury occurs in around 1%–4% of patients treated with ICPi, usually in a pattern of acute tubulo-interstitial nephritis with a lymphocytic infiltrate [79]. Attention needs to be paid to the patient’s baseline creatinine, not just abnormal results per biochemistry ULN. Confounding diagnoses include dehydration, recent i.v. contrast, urinary tract infection, medications, hypotension, or hypertension. Early consideration for renal biopsy is helpful which may negate the need for steroids and determine whether renal deterioration is related to ICPis or other pathology. Oliguria should prompt inpatient admission for careful fluid balance and plan for access to renal replacement therapy. Steroid wean: begin to wean once creatinine G1; G2 severity episode—wean steroids over 2–4 weeks; G3/4 episode—wean over ≥ 4 weeks. If on steroids for > 4 weeks—PJP prophylaxis, calcium/vitamin D supplementation, gastric protection and check afternoon glucose for hyperglycaemia. *GN screen: ANA, complement C3, C4, ANCA, anti-GBM, hepatitis B and C, HIV, immunoglobulins and protein electrophoresis. ANA, antinuclear antibody; ANCA, anti-neutrophil cytoplasmic antibody; GBM; glomerular basement membrane; GN, glomerulonephritis; HIV, human immunodeficiency virus; ICPi, immune checkpoint inhibitor; irAE, immune-related adverse event; i.v., intravenous; K, potassium; PJP, Pneumocystis jiroveci pneumonia; ULN, upper limit of normal; UPCR, urine protein to creatinine ratio.

Table 2. Summary of recommendations for immune-related toxicities**Immune-related skin toxicity**

- For grade 1–2 skin AEs, continue (at least 1 week) with ICPIs. Start topical emollients, antihistamines in the case of pruritus and/or topical (mild strength) corticosteroid creams. Reinitiate ICPI when \leq grade 1.
- For grade 3 skin AEs, interrupt ICPI and start immediate treatment with topical emollients, antihistamines and high strength corticosteroid creams [II, B].
- For grade 4 skin AEs, discontinue ICPI (permanently), consider admitting patient and always consult dermatologist immediately. Start i.v. corticosteroids [1–2 mg/kg (methyl)prednisone] and taper based on response of AE [II, B].

Immune-related endocrinopathies

- In symptomatic hyperthyroidism patients, usually grade 1 or 2, interrupt ICPI, start beta-blocker therapy (propranolol or atenolol/metoprolol). Restart ICPI when asymptomatic [IV–V, B].
- In the case of hypothyroidism, rarely $>$ grade 2, start HRT depending on the severity (50–100 μ g/day). Increase the dose until TSH is normal. In the case of inflammation of the thyroid gland, start prednisone orally 1 mg/kg. Taper based on recovery of clinical symptoms. Consider interruption of ICPI treatment when symptomatic [IV–V, B].
- In the case of hypophysitis (rarely $>$ grade 2), when headache, diplopia or other neurological symptoms are present, start (methyl)prednisone 1 mg/kg orally and taper over 2–4 weeks. Start HRT depending on the affected hormonal axis (levothyroxine, hydrocortisol, testosterone) [V, B].
- In patients with type I DM grade 3 to 4 [ketoacidotic (sub)coma], admit to hospital immediately and start treatment of newly onset type I DM [I, A]. Role of corticosteroids in preventing complete loss of insulin producing cells is unknown and not recommended.

Immune-related hepatotoxicity

- For grade 2 hepatitis, withhold ICPI and monitor AST/ALT levels closely (1–2 times/week). When no improvement over 1 week, start (methyl)prednisone (0.5–1 mg/kg). Taper over several weeks under close monitoring of AST/ALT and bilirubin [IV–V, B].
- For grade 3 hepatitis, discontinue ICPI and immediately start with (methyl)prednisone 1–2 mg/kg. When no improvement in 2–3 days, add MMF (1000 mg 3 \times daily). Taper immunosuppression over 4–6 weeks under close monitoring of AST/ALT and bilirubin [IV–V, B].
- For grade 4 hepatitis, permanently discontinue ICPI, admit patient to the hospital and initiate (methyl)prednisone 2 mg/kg i.v. Add MMF if no improvement is observed within 2–3 days. Consult hepatologist if no improvement under double immunosuppression. Other immunosuppressive drugs to consider are ATG and tacrolimus. Consult or refer patient to an experienced centre. Taper over 6 weeks under close monitoring of liver tests [IV–V, B].

Gastrointestinal hepatotoxicity

- In patients with non-severe diarrhoea (grade 1), ICPI can be continued. Treatment with anti-diarrhoeal medication (e.g. loperamide) should be prescribed [IV–V, B].
- In grade 2 diarrhoea, ICPI should be interrupted and the patient should start with corticosteroids depending on the severity and other symptoms (either budesonide or oral corticosteroids 1 mg/kg). In the case of no improvement within 3–5 days, colonoscopy should be carried out and, in the case of colitis, infliximab 5 mg/kg should be administered [IV–V, B].
- In patients with severe diarrhoea (grade 3 to 4), permanently discontinue ICPI. Admit patient to the hospital and initiate (methyl)prednisone 2 mg/kg i.v. Add MMF if improvement is observed within 2–3 days. Consult a hepatologist if no improvement under double immunosuppression. Other immunosuppressive drugs to consider are ATG and tacrolimus. Consult or refer patient to an experienced centre. Taper over 6 weeks under close monitoring of liver tests [IV–V, B].

Immune-related pneumonitis

- In grade 1 and 2 pneumonitis, interrupt ICPI therapy, try to rule out infection and start with prednisone 1–2 mg/kg orally. Taper over 4–6 weeks [IV–V, B].
- In grade 3 and 4 pneumonitis, discontinue ICPI permanently, admit the patient to the hospital, even ICU if necessary and immediately start high-dose (methyl)prednisone 2–4 mg/kg i.v. Add infliximab, MMF or cyclophosphamide in the case of deterioration under steroids. Taper over a period of 4–6 weeks [IV–V, B].

Neurological toxicity

- In the case of mild neurological AEs, withhold ICPI and perform work-up (MRI scan, lumbar puncture) to define nature of neurotoxicity. In the case of deterioration or severe neurological symptoms, admit the patient and start (methyl)prednisone 1–2 mg/kg orally or i.v. In the case of Guillain-Barré or myasthenia-like symptoms, consider adding plasmapheresis or i.v. Ig [V, B].

Cardiac toxicity

- When a myocarditis is suspected, admit the patient and immediately start high-dose (methyl)prednisone (1–2 mg/kg). In the case of deterioration, consider adding another immunosuppressive drug (MMF or tacrolimus) [V, B].

Rheumatological toxicity

- For mild arthralgia, start NSAIDs, and in the case of no improvement, consider low dose steroids (10–20 mg prednisone). In the case of severe polyarthritis, refer patient to or consult a rheumatologist and start prednisone 1 mg/kg. Sometimes infliximab or another anti-TNF α drug is required for improvement of arthritis [V, B].

Renal toxicity

- In case of nephritis, rule out other causes of renal failure first. Interrupt or permanently discontinue ICPI depending on the severity of the renal insufficiency. Stop other nephrotoxic drugs. Start (methyl)prednisone 1–2 mg/kg. Consider renal biopsy to confirm diagnosis [V, B].

AE, adverse event; ALT, alanine transaminase; AST, aspartate transaminase; ATG, anti-thymocyte globulin; DM, diabetes mellitus; HRT, hormone replacement therapy; ICPI, immune checkpoint inhibitor; ICU, intensive care unit; Ig, immunoglobulin; i.v. intravenous; MMF, mycophenolate mofetil; MRI, magnetic resonance imaging; NSAIDs, nonsteroidal anti-inflammatory drugs; TNF α , tumour necrosis factor alpha; TSH, thyroid-stimulating hormone.

Table 3. Levels of evidence and grades of recommendation (adapted from the Infectious Diseases Society of America-United States Public Health Service Grading System^a)

Levels of evidence	
I	Evidence from at least one large randomised, controlled trial of good methodological quality (low potential for bias) or meta-analyses of well-conducted randomised trials without heterogeneity
II	Small randomised trials or large randomised trials with a suspicion of bias (lower methodological quality) or meta-analyses of such trials or of trials demonstrated heterogeneity
III	Prospective cohort studies
IV	Retrospective cohort studies or case-control studies
V	Studies without control group, case reports, expert opinions
Grades of recommendation	
A	Strong evidence for efficacy with a substantial clinical benefit, strongly recommended
B	Strong or moderate evidence for efficacy but with a limited clinical benefit, generally recommended
C	Insufficient evidence for efficacy or benefit does not outweigh the risk or the disadvantages (adverse events, costs, ...). optional
D	Moderate evidence against efficacy or for adverse outcome, generally not recommended
E	Strong evidence against efficacy or for adverse outcome, never recommended

^aBy permission of the Infectious Diseases Society of America [88].

Acknowledgements

We thank Prof. M. Gore and Dr L. Spain from the Royal Marsden Hospital, London, UK, for their help with developing the up-to-date AE management algorithms.

Disclosure

FC has reported being a board member of Merck Sharpe & Dohme and Bristol-Myers Squibb and honoraria from Bristol-Myers Squibb; CR has reported consultancy for Roche, Bristol-Myers Squibb, Amgen, Merck Sharpe & Dohme, Novartis and Merck; KK has reported lecture honoraria and/or consultancy from AstraZeneca, Bristol-Myers Squibb, Boehringer Ingelheim, Eli Lilly, Merck KGaA, Merck Sharpe & Dohme, Novartis, Pfizer, Roche and Roche Diagnostics; JL has reported honoraria and research grants from Bristol-Myers Squibb, Merck Sharpe & Dohme, Novartis, Pfizer, Eisai, GlaxoSmithKline, Kymab, Roche/Genentech, Secarna, Fabre and EUSA Pharma; JH, SP and KJ has reported honoraria from Amgen, Merck, MSD, Helsinn, Tesaro and Hexal and being a member of the advisory board of Merck, MSD, Helsinn and Tesaro.

References

- Hodi FS, O'Day SJ, McDermott DF et al. Improved survival with ipilimumab in patients with metastatic melanoma. *N Engl J Med* 2010; 363: 711–723.
- Larkin J, Chiarion Sileni V, Gonzalez R et al. Combined nivolumab and ipilimumab or monotherapy in untreated melanoma. *N Engl J Med* 2015; 373: 23–34.
- Wolchok JD, Neyns B, Linette G et al. Ipilimumab monotherapy in patients with pretreated advanced melanoma: a randomised, double-blind, multicentre, phase 2, dose-ranging study. *Lancet Oncol* 2010; 11: 155–164.
- Eggermont AM, Chiarion Sileni V, Grob JJ et al. Prolonged survival in stage III melanoma with ipilimumab adjuvant therapy. *N Engl J Med* 2016; 375: 1845–1855.
- Naidoo J, Page DB, Li BT et al. Toxicities of the anti-PD-1 and anti-PD-L1 immune checkpoint antibodies. *Ann Oncol* 2015; 26: 2375–2391.
- Robert C, Long GV, Brady B et al. Nivolumab in previously untreated melanoma without BRAF mutation. *N Engl J Med* 2015; 372: 320–330.
- Weber JS, Hodi FS, Wolchok JD et al. Safety profile of nivolumab monotherapy: a pooled analysis of patients with advanced melanoma. *J Clin Oncol* 2017; 35: 785–792.
- Brahmer J, Reckamp KL, Baas P et al. Nivolumab versus docetaxel in advanced squamous-cell non-small-cell lung cancer. *N Engl J Med* 2015; 373: 123–135.
- Borghaei H, Paz-Ares L, Horn L et al. Nivolumab versus docetaxel in advanced nonsquamous non-small-cell lung cancer. *N Engl J Med* 2015; 373: 1627–1639.
- Motzer RJ, Escudier B, McDermott DF et al. Nivolumab versus everolimus in advanced renal-cell carcinoma. *N Engl J Med* 2015; 373: 1803–1813.
- Ribas A, Puzanov I, Dummer R et al. Pembrolizumab versus investigator-choice chemotherapy for ipilimumab-refractory melanoma (KEYNOTE-002): a randomised, controlled, phase 2 trial. *Lancet Oncol* 2015; 16: 908–918.
- Robert C, Schachter J, Long GV et al. Pembrolizumab versus ipilimumab in advanced melanoma. *N Engl J Med* 2015; 372: 2521–2532.
- Herbst RS, Baas P, Kim DW et al. Pembrolizumab versus docetaxel for previously treated, PD-L1-positive, advanced non-small-cell lung cancer (KEYNOTE-010): a randomised controlled trial. *Lancet* 2016; 387: 1540–1550.
- Reck M, Rodríguez-Abreu D, Robinson AG et al. Pembrolizumab versus chemotherapy for PD-L1-positive non-small-cell lung cancer. *N Engl J Med* 2016; 375: 1823–1833.
- Eigentler TK, Hassel JC, Berking C et al. Diagnosis, monitoring and management of immune-related adverse drug reactions of anti-PD-1 antibody therapy. *Cancer Treat Rev* 2016; 45: 7–18.
- Menzies AM, Johnson DB, Ramanujam S et al. Anti-PD-1 therapy in patients with advanced melanoma and preexisting autoimmune disorders or major toxicity with ipilimumab. *Ann Oncol* 2017; 28: 368–376.
- Bowyer S, Prithviraj P, Lorigan P et al. Efficacy and toxicity of treatment with the anti-CTLA-4 antibody ipilimumab in patients with metastatic melanoma after prior anti-PD-1 therapy. *Br J Cancer* 2016; 114: 1084–1089.
- Horvat TZ, Adel NG, Dang TO et al. Immune-related adverse events, need for systemic immunosuppression, and effects on survival and time to treatment failure in patients with melanoma treated with ipilimumab at Memorial Sloan Kettering Cancer Center. *J Clin Oncol* 2015; 33: 3193–3198.
- Lacouture ME, Wolchok JD, Yosipovitch G et al. Ipilimumab in patients with cancer and the management of dermatologic adverse events. *J Am Acad Dermatol* 2014; 71: 161–169.
- Belum VR, Benhuri B, Postow MA et al. Characterisation and management of dermatologic adverse events to agents targeting the PD-1 receptor. *Eur J Cancer* 2016; 60: 12–25.
- Hua C, Boussemart L, Mateus C et al. Association of vitiligo with tumor response in patients with metastatic melanoma treated with pembrolizumab. *JAMA Dermatol* 2016; 152: 45–51.
- Boutros C, Tarhini A, Routier E et al. Safety profiles of anti-CTLA-4 and anti-PD-1 antibodies alone and in combination. *Nat Rev Clin Oncol* 2016; 13: 473–486.
- Sibaud V, Meyer N, Lamant L et al. Dermatologic complications of anti-PD-1/PD-L1 immune checkpoint antibodies. *Curr Opin Oncol* 2016; 28: 254–263.

24. Curry JL, Tetzlaff MT, Nagarajan P et al. Diverse types of dermatologic toxicities from immune checkpoint blockade therapy. *J Cutan Pathol* 2017; 44: 158–176.
25. Shi VJ, Rodic N, Gettinger S et al. Clinical and histologic features of lichenoid mucocutaneous eruptions due to anti-programmed cell death 1 and anti-programmed cell death ligand 1 immunotherapy. *JAMA Dermatol* 2016; 152: 1128–1136.
26. Tetzlaff MT, Nagarajan P, Chon S et al. Lichenoid dermatologic toxicity from immune checkpoint blockade therapy. A detailed examination of the clinicopathologic features. *Am J Dermatopathol* 2017; 39: 121–129.
27. Uemura M, Faisal F, Haymaker C et al. A case report of Grover's disease from immunotherapy—a skin toxicity induced by inhibition of CTLA-4 but not PD-1. *J Immunother Cancer* 2016; 4: 55.
28. Osorio JC, Ni A, Chaft JE et al. Antibody-mediated thyroid dysfunction during T-cell checkpoint blockade in patients with non-small-cell lung cancer. *Ann Oncol* 2017; 28: 583–589.
29. Torino F, Corsello SM, Salvatori R. Endocrinological side-effects of immune checkpoint inhibitors. *Curr Opin Oncol* 2016; 28: 278–287.
30. Iwama S, De Remigis A, Callahan MK et al. Pituitary expression of CTLA-4 mediates hypophysitis secondary to administration of CTLA-4 blocking antibody. *Sci Transl Med* 2014; 6: 230ra45.
31. Mellati M, Eaton KD, Brooks-Worrell BM et al. Anti-PD-1 and anti-PDL-1 monoclonal antibodies causing type 1 diabetes. *Diabetes Care* 2015; 38: e137–e138.
32. Johnchilla M, Misdraji J, Pratt DS et al. Ipilimumab-associated hepatitis: clinicopathologic characterization in a series of 11 cases. *Am J Surg Pathol* 2015; 39: 1075–1084.
33. Kim KW, Ramaiya NH, Krajewski KM et al. Ipilimumab associated hepatitis: imaging and clinicopathologic findings. *Invest New Drugs* 2013; 31: 1071–1077.
34. Chmiel KD, Suan D, Liddle C et al. Resolution of severe ipilimumab-induced hepatitis after antithymocyte globulin therapy. *J Clin Oncol* 2011; 29: e237–e240.
35. Gupta A, De Felice KM, Loftus EV, Jr, Khanna S. Systematic review: colitis associated with anti-CTLA-4 therapy. *Aliment Pharmacol Ther* 2015; 42: 406–417.
36. Beck KE, Blansfield JA, Tran KQ et al. Enterocolitis in patients with cancer after antibody blockade of cytotoxic T-lymphocyte-associated antigen 4. *J Clin Oncol* 2006; 24: 2283–2289.
37. Yervoy: Highlights of prescribing information, 2011, pp. 1–20. https://www.accessdata.fda.gov/drugsatfda_docs/label/2011/125377s00001bl.pdf (30 May 2017, date last accessed).
38. Marthey L, Mateus C, Mussini C et al. Cancer immunotherapy with anti-CTLA-4 monoclonal antibodies induces an inflammatory bowel disease. *J Crohns Colitis* 2016; 10: 395–401.
39. Johnson DB, Sullivan RJ, Ott PA et al. Ipilimumab therapy in patients with advanced melanoma and preexisting autoimmune disorders. *JAMA Oncol* 2016; 2: 234–240.
40. Lord JD, Hackman RC, Moklebus A et al. Refractory colitis following anti-CTLA4 antibody therapy: analysis of mucosal FOXP3+ T cells. *Dig Dis Sci* 2010; 55: 1396–1405.
41. Berman D, Parker SM, Siegel J et al. Blockade of cytotoxic T-lymphocyte antigen-4 by ipilimumab results in dysregulation of gastrointestinal immunity in patients with advanced melanoma. *Cancer Immunol* 2010; 10: 11.
42. Weber J, Thompson JA, Hamid O et al. A randomized, double-blind, placebo-controlled, phase II study comparing the tolerability and efficacy of ipilimumab administered with or without prophylactic budesonide in patients with unresectable stage III or IV melanoma. *Clin Cancer Res* 2009; 15: 5591–5598.
43. Bergqvist V, Hertervig E, Gedeon P et al. Vedolizumab treatment for immune checkpoint inhibitor-induced enterocolitis. *Cancer Immunol Immunother* 2017; 66: 581–592.
44. Lankes K, Hunderfean G, Harrer T et al. Anti-TNF-refractory colitis after checkpoint inhibitor therapy: Possible role of CMV-mediated immunopathogenesis. *Oncoimmunology* 2016; 5: e1128611.
45. Dubin K, Callahan MK, Ren B et al. Intestinal microbiome analyses identify melanoma patients at risk for checkpoint-blockade-induced colitis. *Nat Commun* 2016; 7: 10391.
46. Chaput N, Lepage P, Coutzac C et al. Baseline gut microbiota predicts clinical response and colitis in metastatic melanoma patients treated with ipilimumab. *Ann Oncol* 2017; 28: 1368–1379.
47. Arriola E, Wheeler M, Karydis I et al. Infliximab for IPILIMUMAB-related colitis-letter. *Clin Cancer Res* 2015; 21: 5642–5643.
48. Maker AV, Yang JC, Sherry RM et al. Inpatient dose escalation of anti-CTLA-4 antibody in patients with metastatic melanoma. *J Immunother* 2006; 29: 455–463.
49. Weber JS, D'Angelo SP, Minor D et al. Nivolumab versus chemotherapy in patients with advanced melanoma who progressed after anti-CTLA-4 treatment (CheckMate 037): a randomised, controlled, open-label, phase 3 trial. *Lancet Oncol* 2015; 16: 375–384.
50. Robert C, Ribas A, Wolchok JD et al. Anti-programmed-death-receptor-1 treatment with pembrolizumab in ipilimumab-refractory advanced melanoma: a randomised dose-comparison cohort of a phase 1 trial. *Lancet* 2014; 384: 1109–1117.
51. Gonzalez RS, Salaria SN, Bohannon CD et al. PD-1 inhibitor gastroenterocolitis: case series and appraisal of 'immunomodulatory gastroenterocolitis'. *Histopathology* 2017; 70: 558–567.
52. Collins M, Michot J-M, Danlos F-X. Gastrointestinal immune related adverse events associated with programmed-Death 1 blockade. *J Crohns Colitis* 2017; 11(suppl 1): S237.
53. Hodi FS, Chesney J, Pavlick AC et al. Combined nivolumab and ipilimumab versus ipilimumab alone in patients with advanced melanoma: 2-year overall survival outcomes in a multicentre, randomised, controlled, phase 2 trial. *Lancet Oncol* 2016; 17: 1558–1568.
54. Postow MA, Chesney J, Pavlick AC et al. Nivolumab and ipilimumab versus ipilimumab in untreated melanoma. *N Engl J Med* 2015; 372: 2006–2017.
55. Nishino M, Sholl LM, Hodi FS et al. Anti-PD-1-related pneumonitis during cancer immunotherapy. *N Engl J Med* 2015; 373: 288–290.
56. Vogel WV, Guislain A, Kvistborg P et al. Ipilimumab-induced sarcoidosis in a patient with metastatic melanoma undergoing complete remission. *J Clin Oncol* 2012; 30: e7–e10.
57. Eckert A, Schoeffler A, Dalle S et al. Anti-CTLA4 monoclonal antibody induced sarcoidosis in a metastatic melanoma patient. *Dermatology* 2009; 218: 69–70.
58. Wilgenhof S, Morlion V, Seghers AC et al. Sarcoidosis in a patient with metastatic melanoma sequentially treated with anti-CTLA-4 monoclonal antibody and selective BRAF inhibitor. *Anticancer Res* 2012; 32: 1355–1359.
59. Rizvi NA, Mazières J, Planchard D et al. Activity and safety of nivolumab, an anti-PD-1 immune checkpoint inhibitor, for patients with advanced, refractory squamous non-small-cell lung cancer (CheckMate 063): a phase 2, single-arm trial. *Lancet Oncol* 2015; 16: 257–265.
60. Topalian SL, Hodi FS, Brahmer JR et al. Safety, activity, and immune correlates of anti-PD-1 antibody in cancer. *N Engl J Med* 2012; 366: 2443–2454.
61. Topalian SL, Sznol M, McDermott DF et al. Survival, durable tumor remission, and long-term safety in patients with advanced melanoma receiving nivolumab. *J Clin Oncol* 2014; 32: 1020–1030.
62. Garon EB, Rizvi NA, Hui R et al. Pembrolizumab for the treatment of non-small-cell lung cancer. *N Engl J Med* 2015; 372: 2018–2028.
63. Hazarika M, Chuk MK, Theoret MR et al. U.S. FDA Approval Summary: Nivolumab for treatment of unresectable or metastatic melanoma following progression on ipilimumab. *Clin Cancer Res* 2017; doi: 10.1158/1078-0432.CCR-16-0712 [Epub ahead of print].
64. Keytruda: Highlights of prescribing information, 2016, pp. 1–26 https://www.accessdata.fda.gov/drugsatfda_docs/label/2016/125514s012bl.pdf (30 May 2017, date last accessed).
65. Opdivo: Highlights of prescribing information, 2014, pp. 1–20. https://www.accessdata.fda.gov/drugsatfda_docs/label/2014/125554bl.pdf (30 May 2017, date last accessed).
66. Naidoo J, Wang X, Woo KM et al. Pneumonitis in patients treated with anti-programmed death-1/programmed death ligand 1 therapy. *J Clin Oncol* 2017; 35: 709–717.
67. Gettinger SN, Horn L, Gandhi L et al. Overall survival and long-term safety of nivolumab (anti-programmed death 1 antibody, BMS-936558, ONO-4538) in patients with previously treated advanced non-small-cell lung cancer. *J Clin Oncol* 2015; 33: 2004–2012.

68. Tirumani SH, Ramaiya NH, Keraliya A et al. Radiographic profiling of immune-related adverse events in advanced melanoma patients treated with ipilimumab. *Cancer Immunol Res* 2015; 3: 1185–1192.
69. Berthod G, Lazor R, Letovanec I et al. Pulmonary sarcoid-like granulomatosis induced by ipilimumab. *J Clin Oncol* 2012; 30: e156–e159.
70. Champiat S, Lambotte O, Barreau E et al. Management of immune checkpoint blockade dysimmune toxicities: a collaborative position paper. *Ann Oncol* 2016; 27: 559–574.
71. Postow MA. Managing immune checkpoint-blocking antibody side effects. *Am Soc Clin Oncol Educ Book* 2015; 35: 76–83.
72. Johnson DB, Balko JM, Compton ML et al. Fulminant myocarditis with combination immune checkpoint blockade. *N Engl J Med* 2016; 375: 1749–1755.
73. Zimmer L, Goldinger SM, Hofmann L et al. Neurological, respiratory, musculoskeletal, cardiac and ocular side-effects of anti-PD-1 therapy. *Eur J Cancer* 2016; 60: 210–225.
74. Tadokoro T, Keshino E, Makiyama A et al. Acute lymphocytic myocarditis with anti-PD-1 antibody nivolumab. *Circ Heart Fail* 2016; 9: e003514.
75. Läubli H, Balmelli C, Bossard M et al. Acute heart failure due to autoimmune myocarditis under pembrolizumab treatment for metastatic melanoma. *J Immunotherapy Cancer* 2015; 3: 11.
76. Spain L, Diem S, Larkin J. Management of toxicities of immune checkpoint inhibitors. *Cancer Treat Rev* 2016; 44: 51–60.
77. Hofmann L, Forschner A, Loquai C et al. Cutaneous, gastrointestinal, hepatic, endocrine, and renal side-effects of anti-PD-1 therapy. *Eur J Cancer* 2016; 60: 190–209.
78. Murakami N, Motwani S, Riella LV. Renal complications of immune checkpoint blockade. *Curr Probl Cancer* 2017; 41: 100–110.
79. Cortazar FB, Marrone KA, Troxell ML et al. Clinicopathological features of acute kidney injury associated with immune checkpoint inhibitors. *Kidney Int* 2016; 90: 638–647.
80. Heo MH, Kim HK, Lee H, Ahn MJ. Antineutrophil cytoplasmic antibody-associated rapid progressive glomerulonephritis after pembrolizumab treatment in thymic epithelial tumor: a case report. *J Thorac Oncol* 2017; pii: S1556-0864(17): 30215–0.
81. Antoun J, Titah C, Cochereau I. Ocular and orbital side-effects of checkpoint inhibitors: a review article. *Curr Opin Oncol* 2016; 28: 288–294.
82. Shiuan E, Beckermann KE, Ozgun A et al. Thrombocytopenia in patients with melanoma receiving immune checkpoint inhibitor therapy. *J Immunotherapy Cancer* 2017; 5: 8.
83. Helgadottir H, Kis L, Ljungman P et al. Lethal aplastic anemia caused by dual immune checkpoint blockade in metastatic melanoma. *Ann Oncol* 2017; 28: 1672–1673.
84. Palla AR, Kennedy D, Mosharraf H, Doll D. Autoimmune hemolytic anemia as a complication of nivolumab therapy. *Case Rep Oncol* 2017; 9: 691–697.
85. Lipson EJ, Bagnasco SM, Moore J, Jr et al. Tumor regression and allograft rejection after administration of anti-PD-1. *N Engl J Med* 2016; 374: 896–898.
86. Weber JS, Kähler KC, Hauschild A. Management of immune-related adverse events and kinetics of response with ipilimumab. *J Clin Oncol* 2012; 30: 2691–2697.
87. Larkin J et al. Efficacy and safety in key patient subgroups of nivolumab (NIVO) alone or combined with ipilimumab (IPI) versus IPI alone in treatment-naïve patients with advanced melanoma (MEL) (CheckMate 067). *Eur J Cancer* 2015; 51 (Suppl 3): S664–S665.
88. Dykewicz CA. Summary of the guidelines for preventing opportunistic infections among hematopoietic stem cell transplant recipients. *Clin Infect Dis* 2001; 33: 139–144.